

NATURAL LAYERING CONCEPT

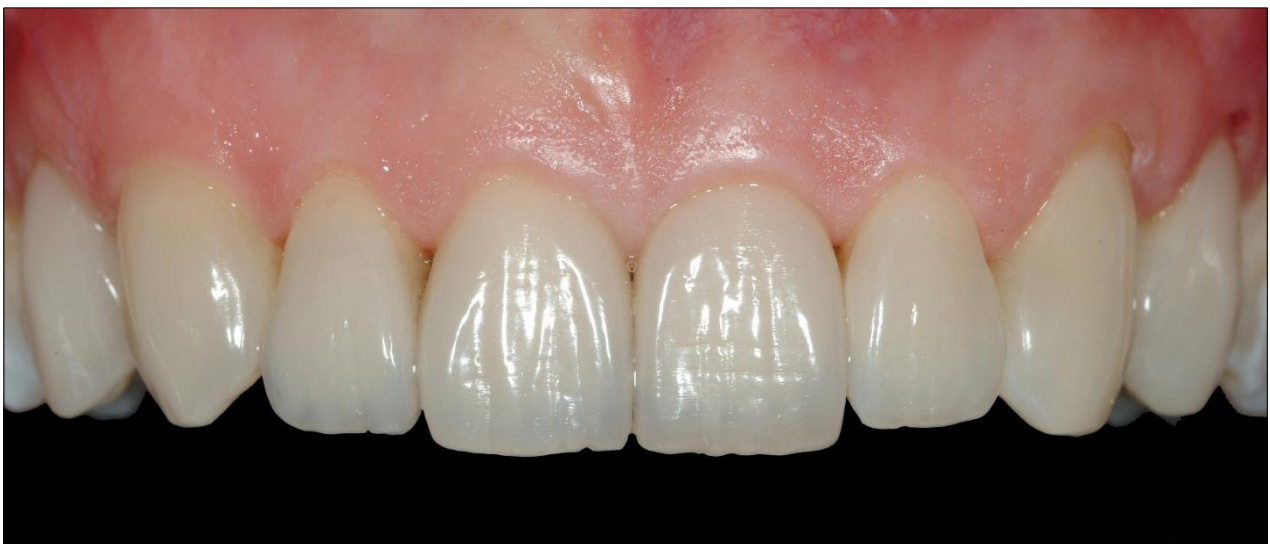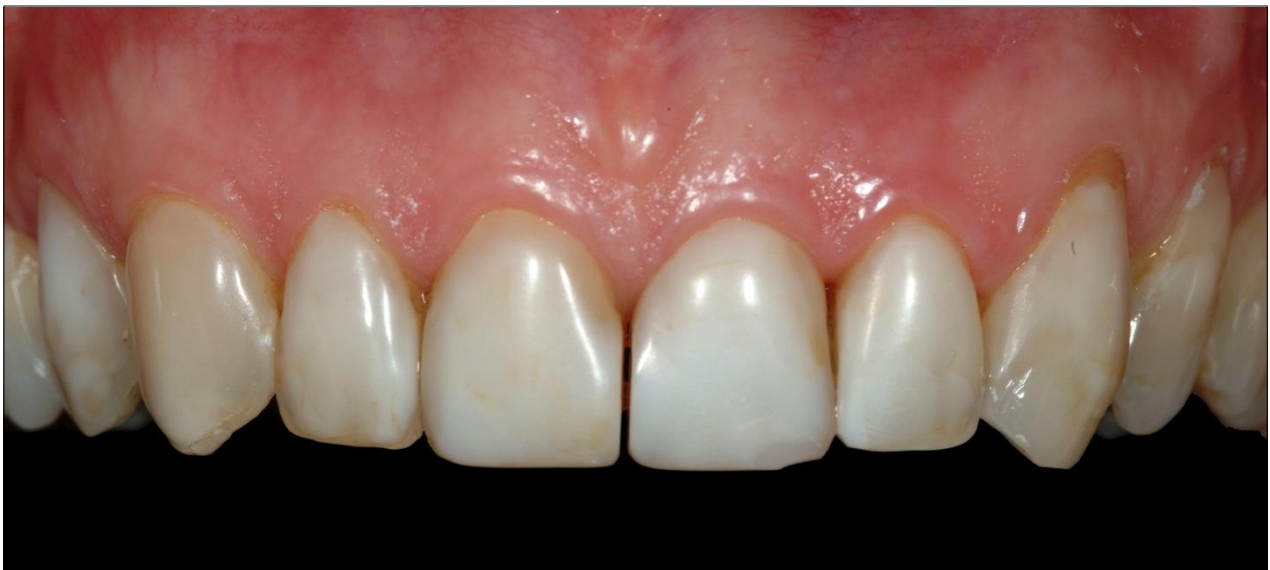a simple, reliable and effective protocol to achieve high esthetics with free-hand bonding techniques

Didier DIETSCHI , D.M.D, PhD, Privat-Docent ¹

Senior lecturer, Department of Cariology & Endodontics, School of Dentistry, University of Geneva, Switzerland.

Adjunct Professor, Department of Comprehensive Care, Case Western University, Cleveland, Ohio.

Private practice & Education Center – The Geneva Smile Center, Switzerland



The **NLC** is an ideal concept to reach great esthetic results using an effective, simple and reliable clinical protocol

Cover page: pre & post-operative views of a smile restored with direct composites veneers, demonstrating the potential of a free-hand approach and new composite technology.

Introduction

Natural, restored or orthodontically enhanced smiles may present esthetic deficiencies that require treatment (Dietschi and Schatz, 1997; Freeman et al, 1996; Heymann, 1997). However, the search for a perfect smile should not drive the clinician to use primarily invasive solutions such as veneers and crowns to resolve all esthetic anomalies since such procedures will have a negative impact on the long-term tooth bio-mechanical behavior and treatment cost. The free-hand option, which is more conservative and cost-effective, should then always be considered as our first choice, if feasible (Dietschi, 1995, 1997, 2001). In this context, composite resins represent the material of choice for young patients and less privileged people, or in any case which require a strictly conservative approach. The natural layering concept has enabled this objective to be achieved in a predictable way by incorporating newly acquired knowledge about natural tissue optical properties into contemporary composite systems. This advance can be regarded as a milestone in operative dentistry as it will give direct composite application a tremendous input, helping a larger number of our patients to receive both conservative and highly aesthetic restorations; this concept was described as the "bio-esthetic" approach. The aim of this article is to illustrate the bio-esthetic philosophy and Natural Layering Concept (NLC) applied to solve two advanced esthetic cases.

The Natural Layering Concept (NLC)

The dentin L*a*b* color measurements of teeth from the "A" "B" and "C" VITA shade groups have suggested that an ideal dentin replacement material should exhibit the following characteristics (Dietschi et al, 2000; Dietschi and Ardu, 2006):

- single hue

- single opacity
- large chroma scale (beyond the 4 chroma levels of the VITA system)

Actually, the variations of a^* and b^* values between various VITA shades seem not to justify the use of distinct dentin colours, at least for a direct composite restorative system. Likewise, the variations of the contrast ratio (opacity-translucency) within a single shade group do not support the use of different dentin opacities (i.e.: translucent, regular or opaque dentins). However, chroma (related to a^* and b^* values) proved to increase from light to dark shades (A1 to A4 or B1 to B3) and then support the concept of a large chroma scale covering all variations of natural dentitions, plus some specific conditions like sclerotic dentin (as found underneath decays, fillings or cervical lesions).

As regard enamel, differences in tissue lightness and translucency proved to vary largely among patients and with tooth age and therefore confirmed the clinical concept of 3 specific enamel types (Ubassy, 1983):

- Young enamel: white tint, natural opalescence, less translucency
- Adult enamel: neutral tint, natural opalescence and intermediary translucency
- Elderly enamel: yellow tint, natural opalescence and higher translucency

This interpretation of human dentin and enamel colorimetric data led to this clinical approach named the "Natural Layering Concept" (NLC), which embraces more accurately the optical and anatomical characteristics of natural teeth (Dietschi, 1995, 1997 and 2001; Dietschi et al, 2000). It actually defines the features of an optimal restorative material aimed to replace dentin and enamel, respectively. Dentins shades should be available in one single hue (close to Vita "A" shade group) with a sufficient range of chroma (covering at least the existing Vita shade range) and presenting opacity similar to natural dentin. Enamel shades should present different tints and opacity levels, tentatively replicating the major variations found in nature. The latest development of this system is the Inspiro (edelweiss DR); previous generations include for instance Miris & Miris 2 (Coltenewhaledent), Ceram-X duo (Dentsply), Asteria (Tokuyama), Aura (SDI) or Enamel HFO/Hri (Micerium).

Case 1

An adult female patient shows esthetically defective composite veneers; she hopes for a significant improvement although having strict financial limitation, driving the treatment plan toward the replacement of existing restorations by a similar free-hand, but improved technique (cover page). A new generation NLC composite system (Inspiro, EdelweissDR) was selected due to its improved optical properties and excellent surface characteristics (easy polishability and good gloss retention) resulting from a new filler technology (homogenous nano-hybrid composite). This material actually has no clustered nano-particles or pre-polymerized fillers which proved to impact negatively the esthetic performance of conventional inhomogeneous nano-hybrid composites.

Rubber dam was applied to optimize adhesive and restorative procedures; actually, such extensive treatment using a direct technique would be less predictable without this isolation procedure, which totally eliminates moisture from breath, crevicular fluid extravasation and possibly slight gingival bleeding. Restorations were made using bi-laminar restorative approach based on one dentin shade (Body i2 for the central and lateral incisors and Body i3 for the canines; selected masses are close to A2 and A3 Vita shades). In addition, a small amount of blue effect shade (Azur, Inspiro) was placed over the dentin mamellons to emulate localized opalescent halo (Fig. 1A).

Finishing and polishing was performed under rubber dam which protect soft tissues for inadvertent aggression. The primary anatomy was corrected with finishing discs of decreasing coarseness (Optidisc, Kerr). When the appropriate proximal and tooth axial profiles were considered optimal, the incisal length and profile was finalized using the same instruments and as well fine finishing diamonds burs. Only 3 instruments were used to finalize the secondary anatomy (micro-texture), starting with a flame, fine diamond (40µm), followed by a prepolymer rubber point (Identoflex minipoint, Kerr) and a diamond impregnated rubber cup (Hi-Luster, Kerr). This simplified instrument sequence led to the good surface anatomy and quality shown on Figures 1B to G.

Case 2

A young male patient presents various esthetic deficiencies. An orthodontic correction helped previously to manage space excess, following congenital lateral

incisor aplasia (Fig. 2A to D). The dento-facial analysis (Fig 3) reveals a serious asymmetry between the face and smile midline, which results from an underlying orthognatic deviation (dental arches and smile are not aligned with the face) which the patient denied to treat. A computer assisted smile analysis was performed with extra-and intra-oral photographs, manipulated and altered within Power Point Software (Microsoft) (Coachman et al, 2011). The remaining esthetic deficiencies following orthodontics could be better identified and the resulting treatment planning explained to the patient (Fig 3C & D).

The following esthetic abnormalities have then to be corrected:

- Tooth axis (upper lateral and canines)
- Tooth forms (upper centrals, canines and lower incisors)
- Tooth color (upper canines)
- Gingival profile (upper premolars)

It was agreed with the patient to conduct the gingival profile correction for upper first premolars at a late stage.

As for the first case, all adhesive and restorative procedures were performed under rubber dam to optimize the quality and longevity of restorations. The same composite system was used (Inspiro), based on a bi-laminar approach (Body and skin shades = dentin and enamel shades) to emulate the natural tooth anatomy and optical characteristics. The body shade (Inspiro i2) was used only for the canines (transformed into laterals incisors) to block the light and translucency within the large pre-existing incisal embrasures. For central incisors (axis and mesio-distal width corrections), only an enamel shade was used (Inspiro skin white & Ivory) as the total layer thickness did not exceed 1 to 1.25mm, which the natural enamel thickness. Pre-contoured matrixes helped to obtain natural proximal contours and emergence profile (Lucifix 775 & 776, Kerr). Finishing and polishing procedures were identical to those used for the case 1. Post-operative views (Fig 4E & 5) demonstrate improved intra-oral and extra-oral smile integration, although the dento-facial asymmetry could not be corrected through restorative procedures. This treatment approach is considered optimal for young patients showing noticeable esthetic deficiencies of an otherwise perfectly healthy dentition.

Discussion - conclusion

The natural layering concept has enabled patient's aesthetic expectations to be fulfilled in a predictable way by incorporating new knowledge about natural tissue optical properties into a new restorative approach for direct, free-hand restorations. It allowed a significant simplification of clinical procedures, making this technique also accessible to general practitioners. This advance can be regarded as a milestone in operative Dentistry, giving a new input to free-hand bonding and helping more patients to receive conservative and highly aesthetic restorations.

Figure legends

Figure 1 A-G: Intra-operative view of the case appearing on the cover page; direct composite veneers were made of 2 only layers (dentin & enamel), with apposition of some blue & white effect shades (Inspiro, Edelweiss DR) following the Natural Layering Concept (NLC). B-C: Post finishing using a fine diamond bur (flame shape) and silicone pre-polishers. C-G: Polished restorations before rubber dam removal and after functional adjustments.

Figure 2 A-D: Pre-operative extra & intra-oral status. The patient has congenitally missing upper laterals and one lower incisor. Following conventional orthodontics treatment, many esthetic problems remain such as tooth axis, forms, proportions and overall smile configuration.

Figure 3 A-D: A-B: Computer assisted smile analysis & design: The most important lines are being drawn (Facial midline, bi-pupillary plane, occlusal plane, tooth axis, etc...) and help to establish the list of major/minor esthetic deficiencies. C-D: Then, new tooth forms and smile configuration can be drawn and partially opacified to show the patient the expected changes (red line shows potential gingival profile correction of the upper first premolars)

Figure 4 A-E: A & B: Chair-side bleaching using 35% hydrogen peroxide was performed to reduce the higher chroma of canines, before proceeding with bonding procedures (A = intra-operative and B= post bleaching view) C & D: Intra-

oral views during direct restorative procedures; rubber-dam secured the quality of adhesion as well as a better access to all surfaces to be additively restored. Rubber dam also protect soft tissues during finishing and polishing procedures. The Natural Layering Concept (NLC) was used to obtain a more predictable and optimal treatment outcome, using the new inspiro system (Edelweiss DR). E: Post treatment view, following the corrections of tooth axis, dimensions and proportions and tooth form of the upper 6 front teeth (previously upper first premolars, canines and central incisors).

Figure 5 A-D: Post-operative extra & intra-oral status. A no prep restorative approach was used which fulfilled the esthetic needs of the patient, using a NLC composite system (inspiro, EdelweissDR) . The treatment outcome is made more predictable, due to the simplicity and reliability of the shading system, including the color taking.

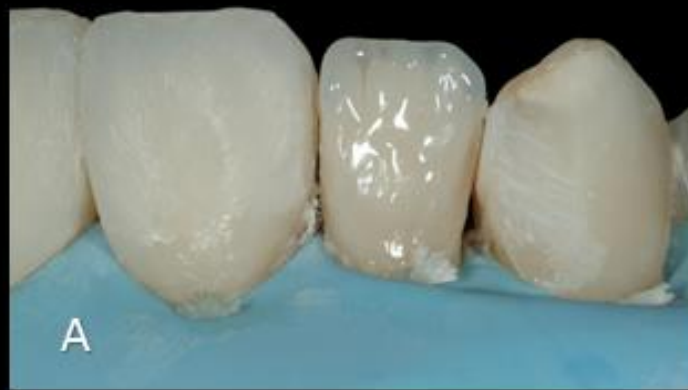
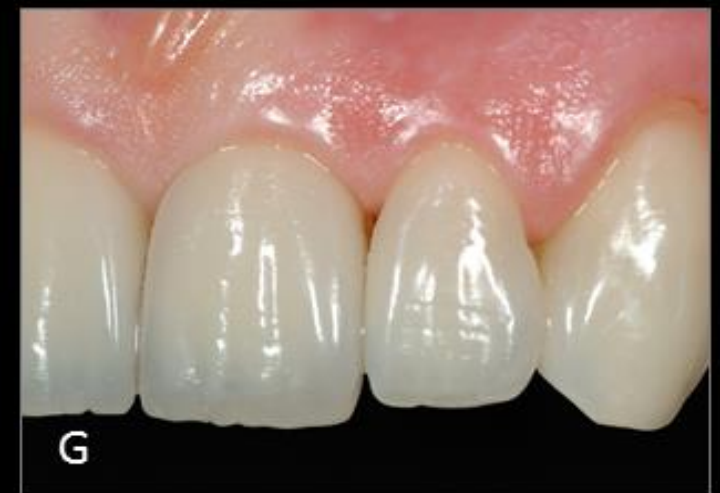
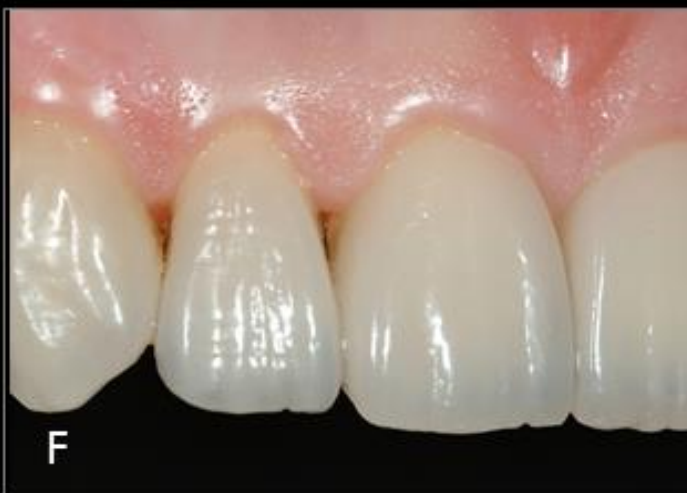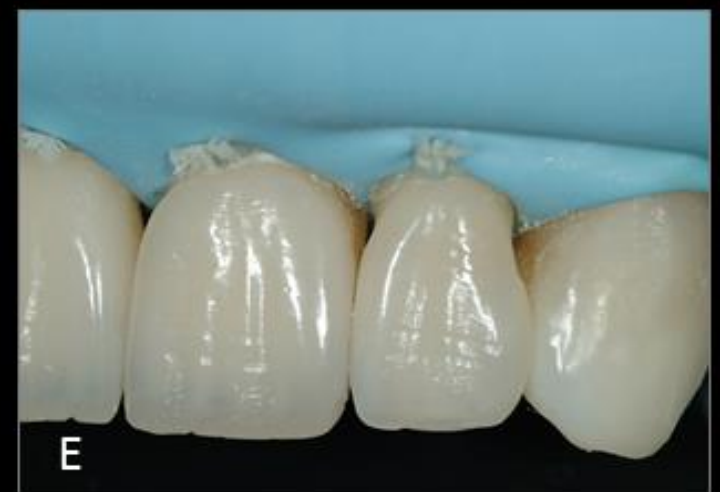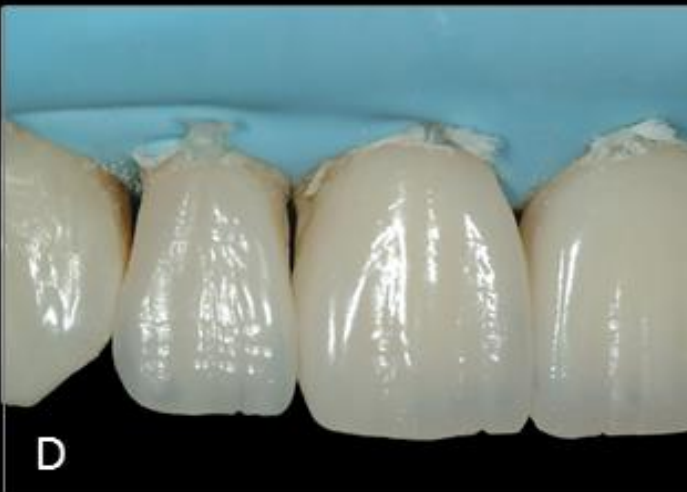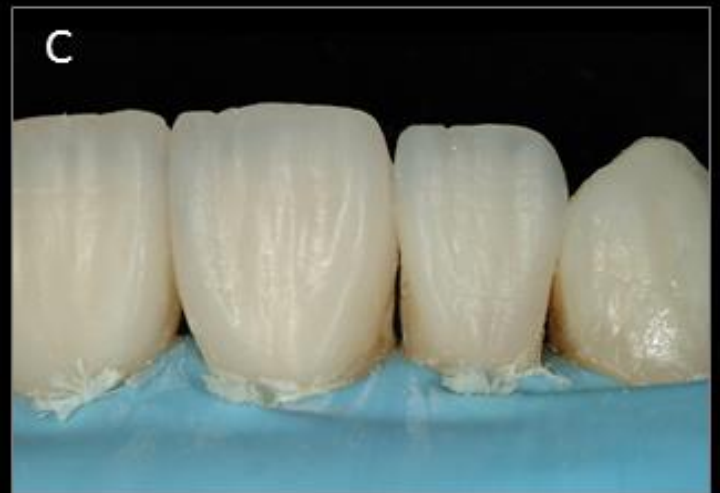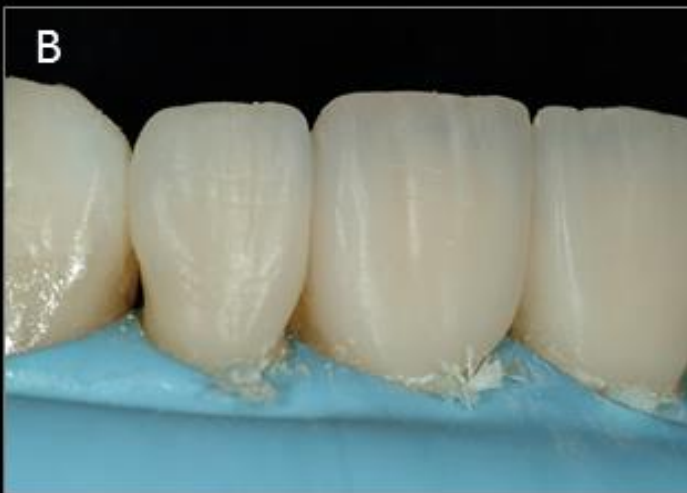Figure 1 A-G: Intra-operative view of the case appearing on the cover page; direct composite veneers were made of 2 only layers (dentin & enamel), with apposition of some blue & iwhite effect shades (Inspiro, Edelweiss DR) following the Natural Layering Concept (NLC). B-C: Post finishing using a fine diamond bur (flamme shape) and silicone pre-polishers. C-G: Polished restorations before rubber dam removal and after functional adjustments.



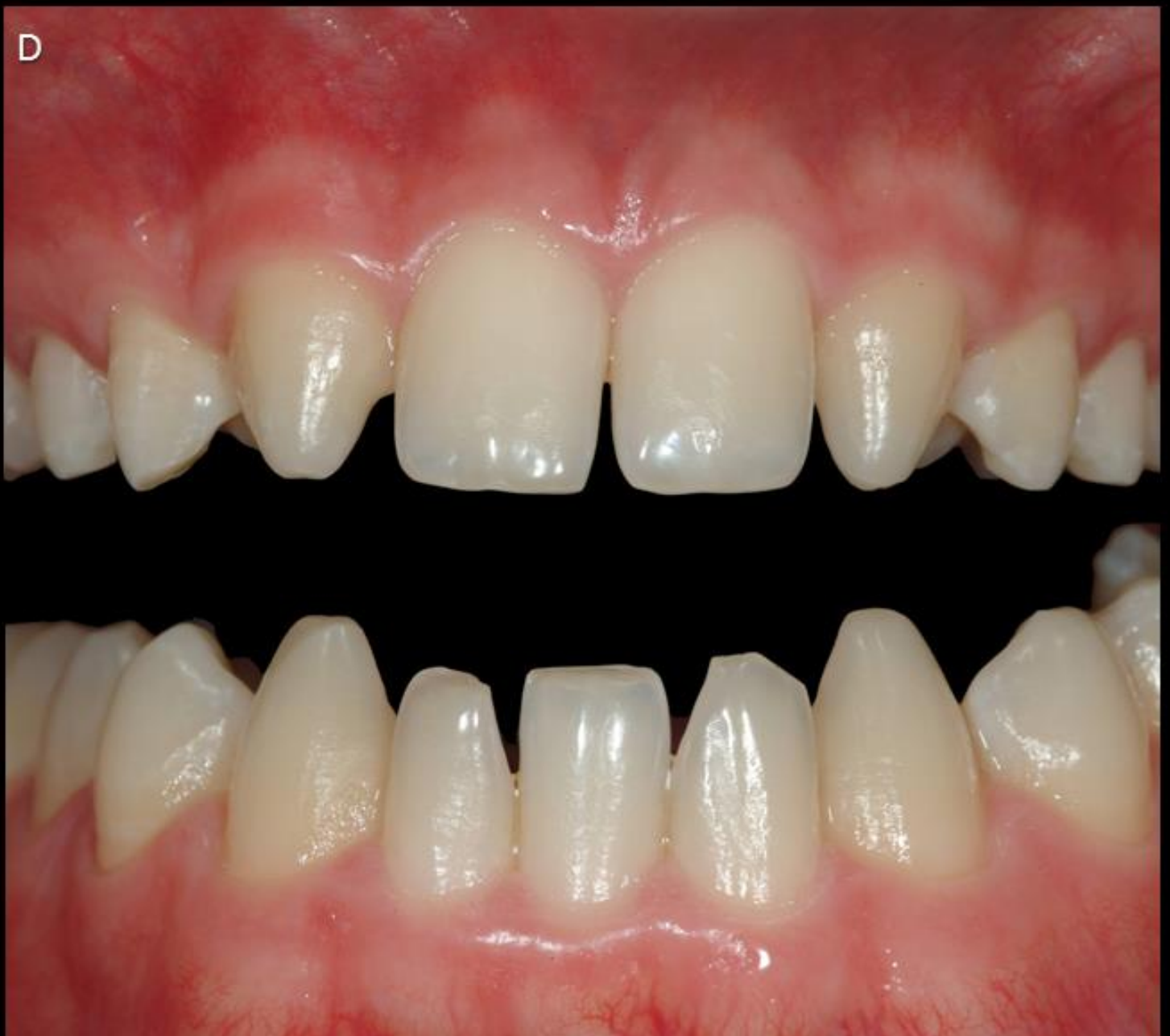
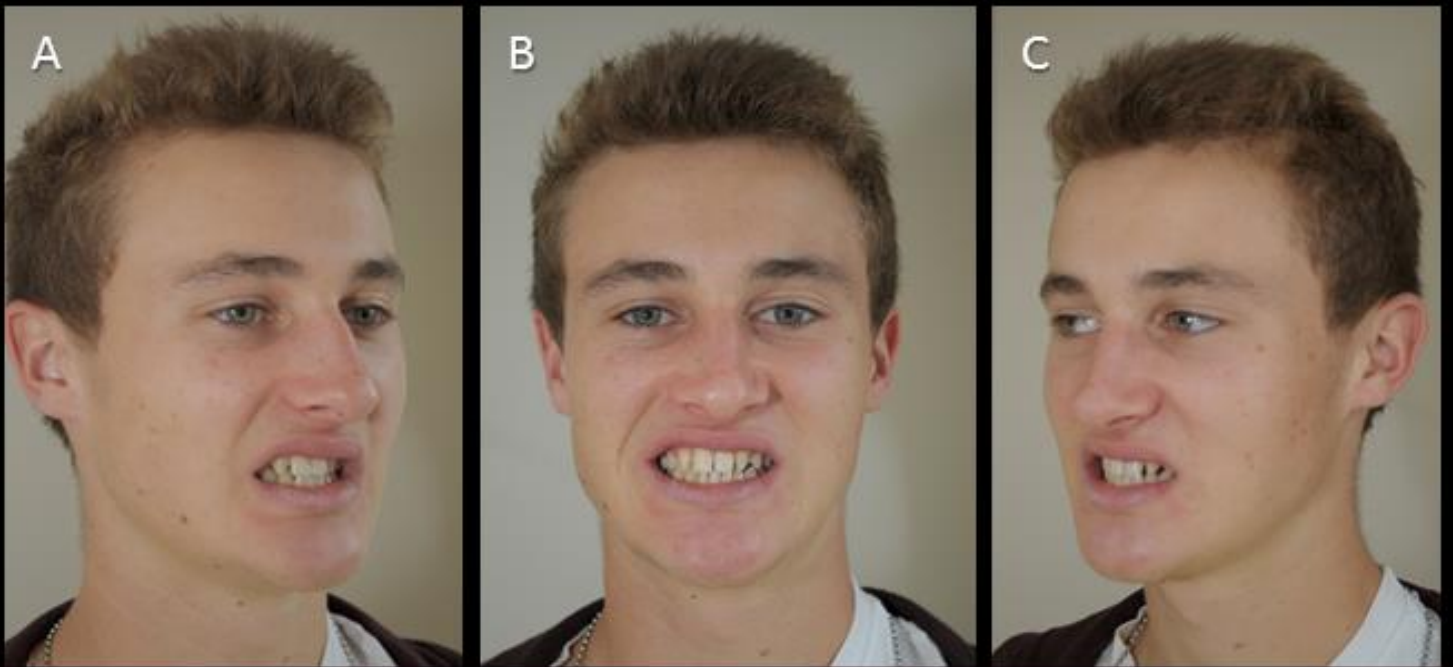
Figure 2 A-D: Pre-operative extra & intra-oral status. The patient has congenitally missing upper laterals and one lower incisor. Following conventional orthodontic treatment, many esthetic problems remain, such as tooth axis, forms, proportions and overall smile configuration.

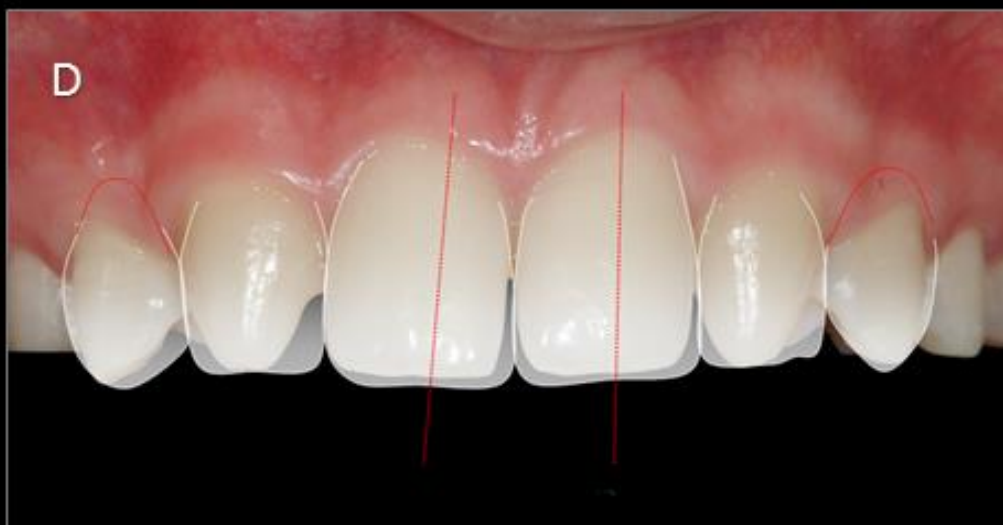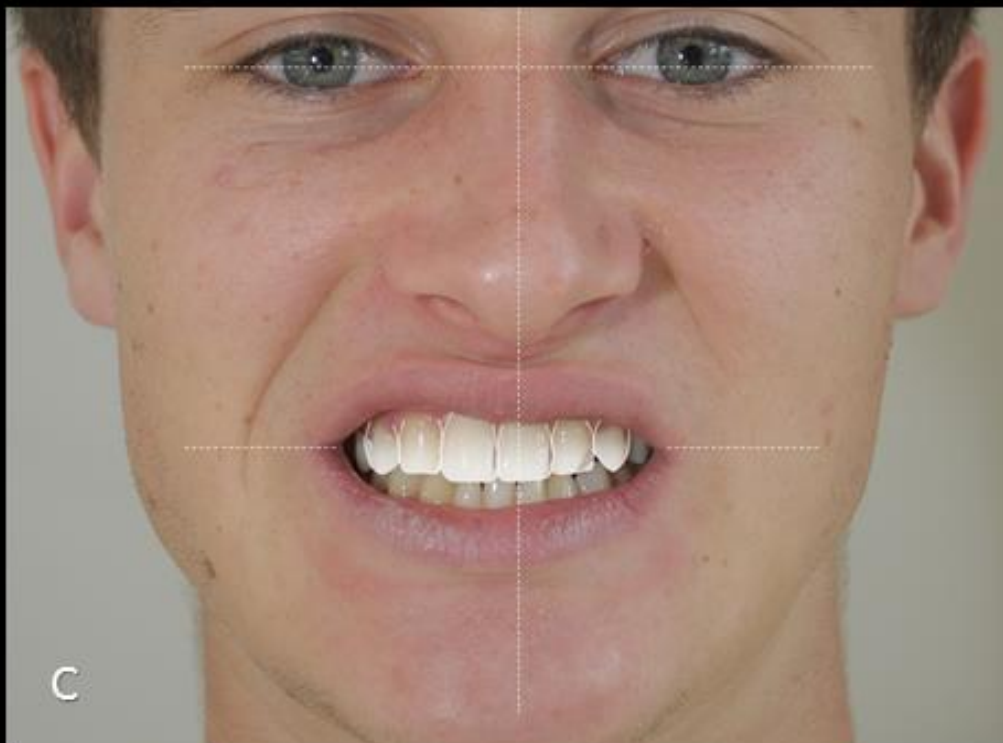
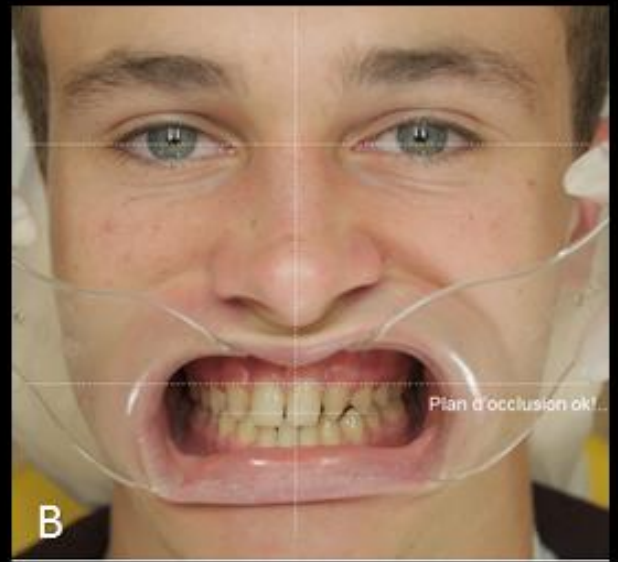
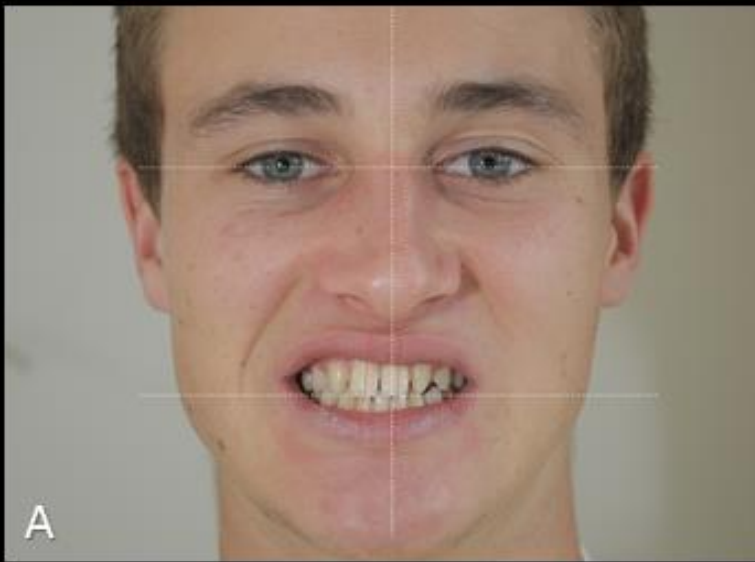


Figure 3 A-D: A-B: Computer assisted smile analysis & design: The most important lines are being drawn (Facial midline, bi-pupillary plane, occlusal plane, tooth axis, etc...) and help to establish the list of major/minor esthetic deficiencies. C-D: Then, new tooth forms and smile configuration can be drawn and partially opacified to show the patient the expected changes (red line shows potential gingival profile correction of the upper first premolars)

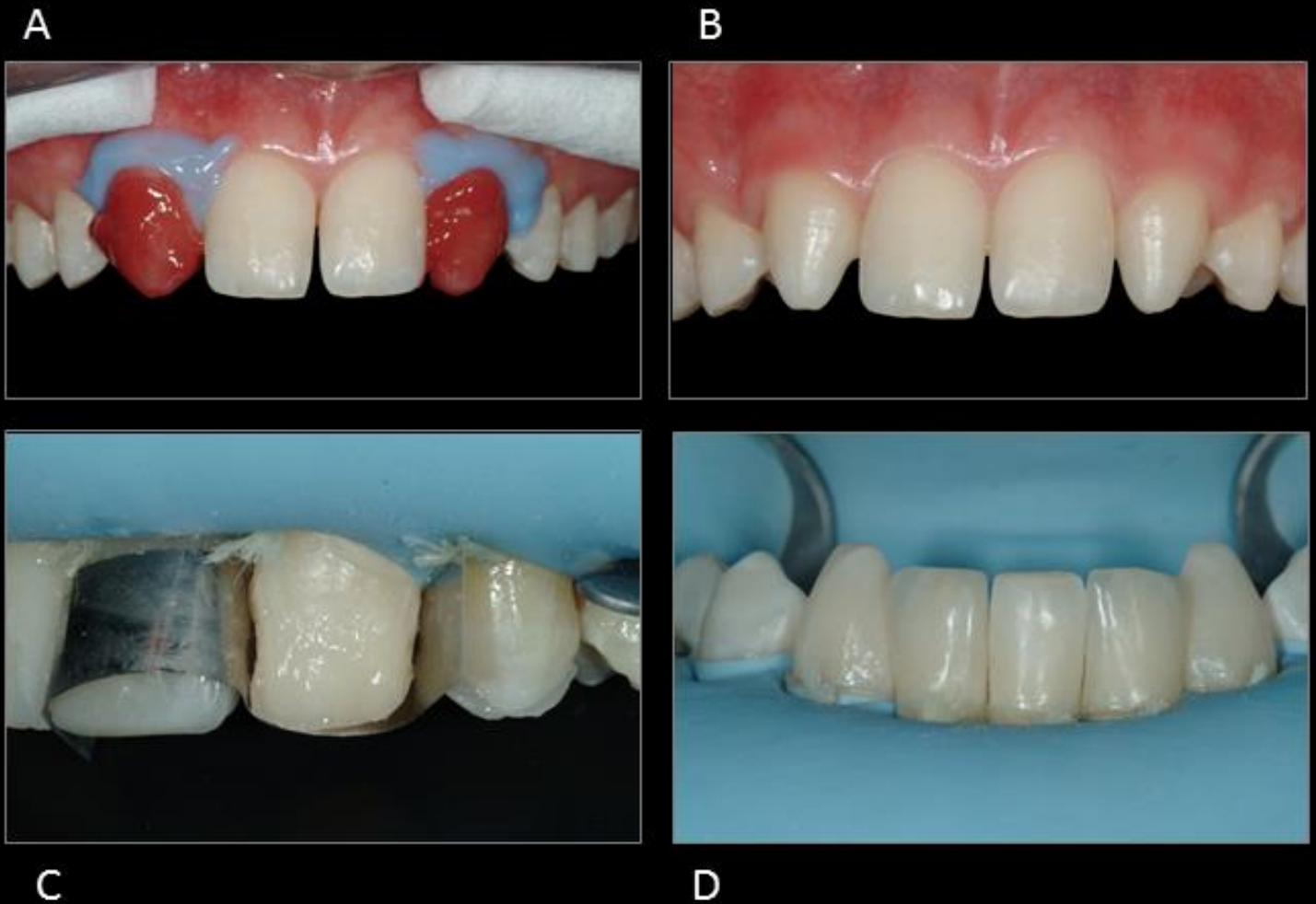

Figure 4 A-D: A & B: Chair-side bleaching using 35% hydrogen peroxide was performed to reduce the higher chroma of canines, before proceeding with bonding procedures (A = intra-operative and B= post bleaching view) C & D: Intra-oral views during direct restorative procedures; rubber-dam secured the quality of adhesion as well as a better access to all surfaces to be additively restored. Rubber dam also protect soft tissues during finishing and polishing procedures. The Natural Layering Concept (NLC) was used to obtain a more predictable and optimal treatment outcome, using the new inspiro system (edelweiss DR)

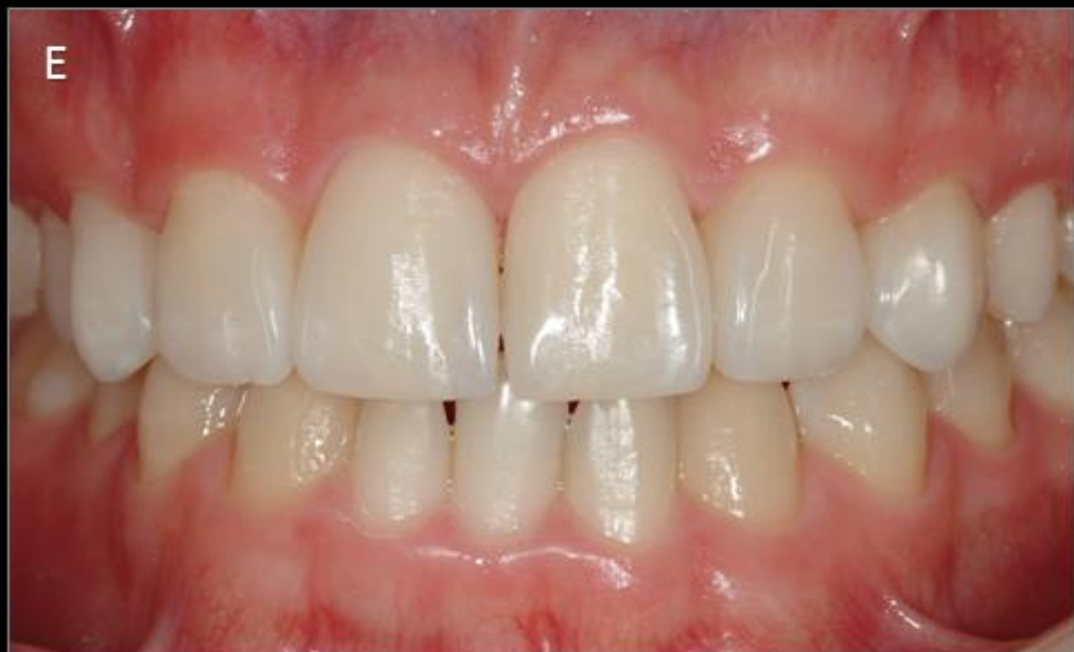
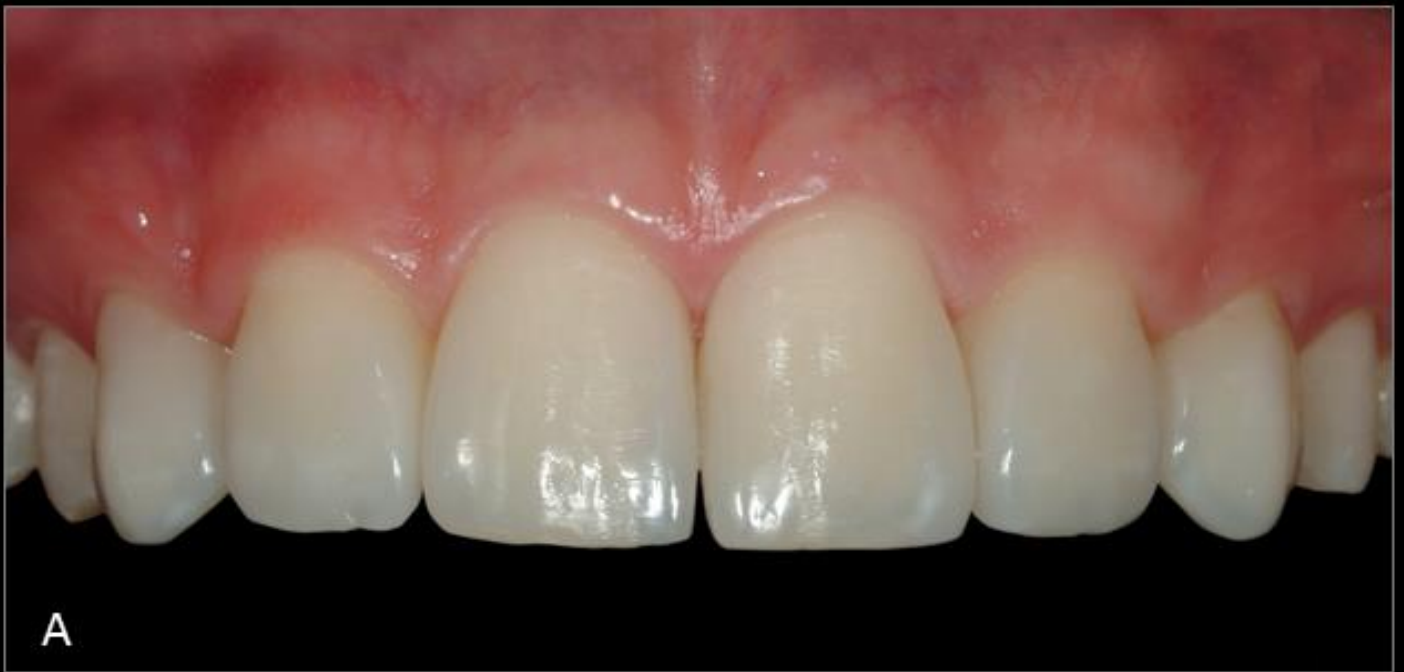
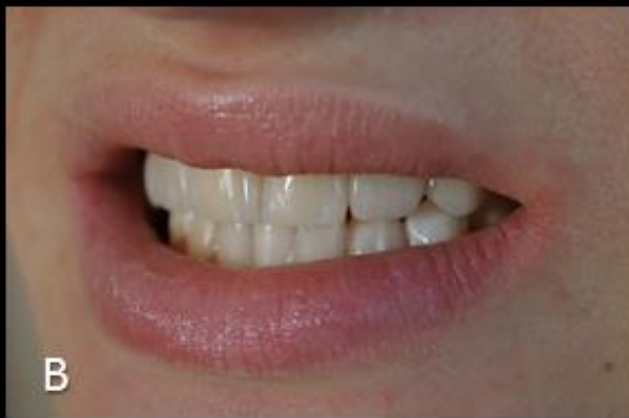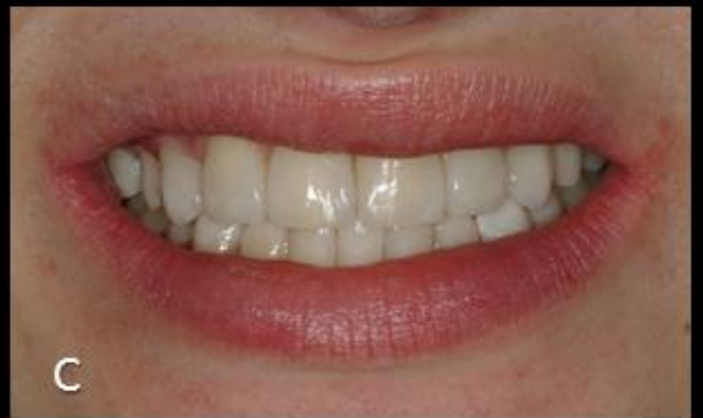Figure 4 E: Post treatment view, following the corrections of tooth axis, dimensions and proportions and tooth form of the upper 6 front teeth (previously upper first premolars, canines and central incisors).



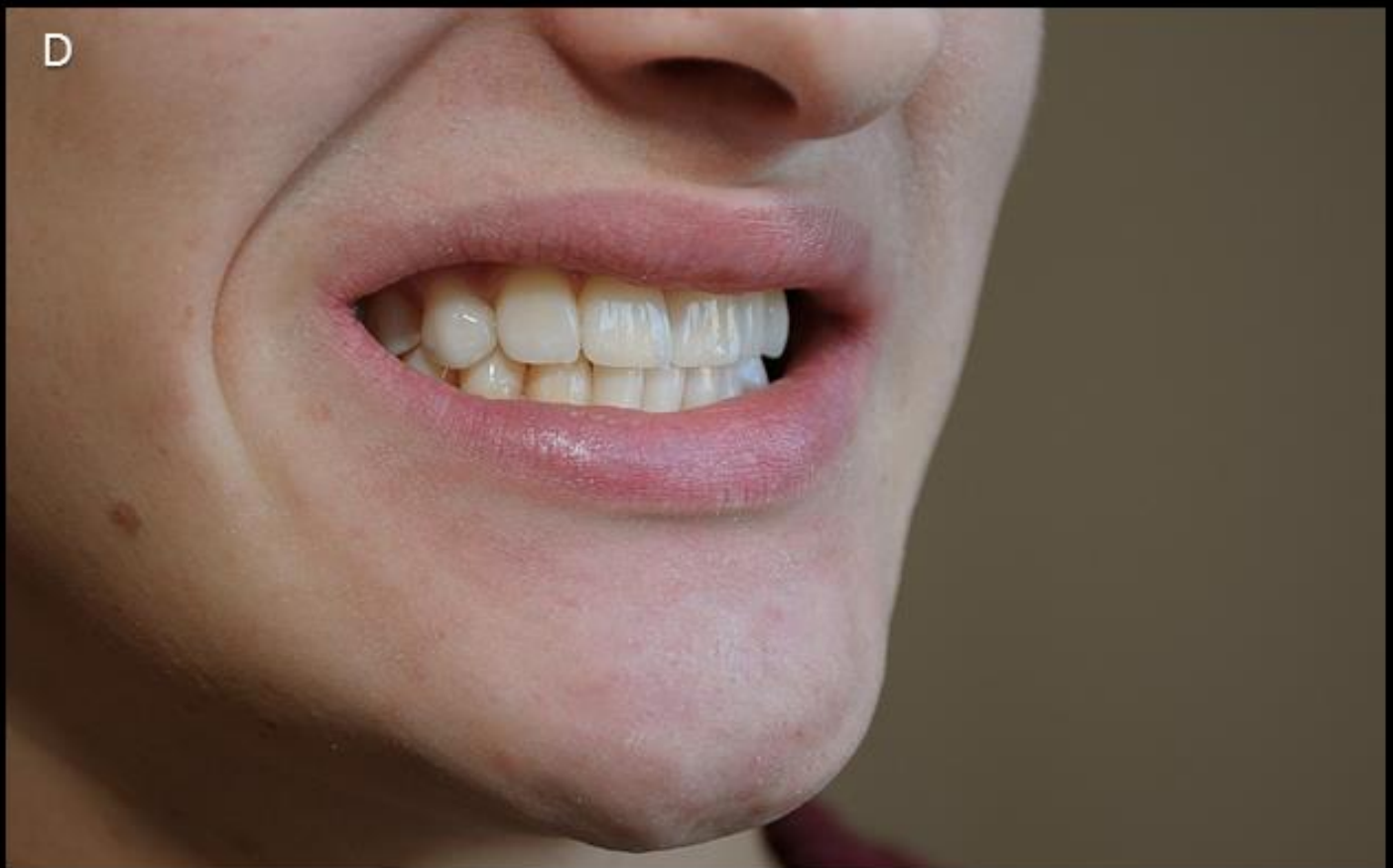A



B



C



D

Figure 5 A-D: Post-operative extra & intra-oral status. A no prep restorative approach was used which fulfilled the esthetic needs of the patient, using a NLC composite system (Inspiro, EdelweissDR) . The treatment outcome is made more predictable, due to the simplicity and reliability of the shading system, including the color taking.

References

Dietschi D, Schatz J P. Current restorative modalities for young patients with missing anterior teeth. Quintessence Int 1997; **28**: 231-240.

Freeman J E, Maskeroni A J, Lorton L. Frequency of Bolton tooth-size discrepancies among orthodontic patients. Am J Orthod Dentofacial Orthop 1996; **110**: 24-27

Dietschi D. Free-hand composite resin restorations: a key to anterior aesthetics. Pract Periodontics Aesthet Dent 1995; **7**: 15-25.

Dietschi D. Free-hand bonding in esthetic treatment of anterior teeth: creating the illusion. J Esthet Dent 1997; **9**: 156-164.

Dietschi D. Layering concepts in anterior composite restorations. J Adhes Dent 2001; **3**: 71-80.

Heymann H O. Conservative concepts for achieving anterior esthetics. J Calif Dent Assoc 1997; **25**: 437-443.

Dietschi D, Ardu S, Krejci I. Exploring the layering concepts for anterior teeth. In Roulet J F, Degrange M (eds). Adhesion - the silent revolution in dentistry. pp 235-251. Berlin: Quintessence Publishing, 2000.

Dietschi D, Ardu S, Krejci I. A new shading concept based on natural tooth color applied to direct composite restorations. Quintessence Int 2006; **37**: 91-102.

Ubassy G. Shape and color: the key to successful ceramic restorations. Berlin: Quintessenz Verlags, 1993.

Coachman C, Van Dooren E, Gürel G, Landsberg C, Calamita AC, Bichacho N. Smile Design: From Digital Treatment Planning to clinical reality. In Interdisciplinary Treatment Planning, Volume II: Comprehensive Case Studies, Cohen M Editor. Quintessence Publishing, Chicago 2011; 119-174.

Address for correspondence:

Didier Dietschi
The Geneva Smile Center
2 Quai Gustave Ador
1207 Geneva
SWITZERLAND

Email: ddietschi@genevasmilecenter.ch