



# A Comprehensive and Conservative Approach for the Restoration of Abrasion and Erosion.

## Part II: Clinical Procedures and Case Report

**Didier Dietschi**, DMD, PhD, Privat-docent

Senior Lecturer, Department of Cariology & Endodontics, School of Dentistry, University of Geneva, Switzerland

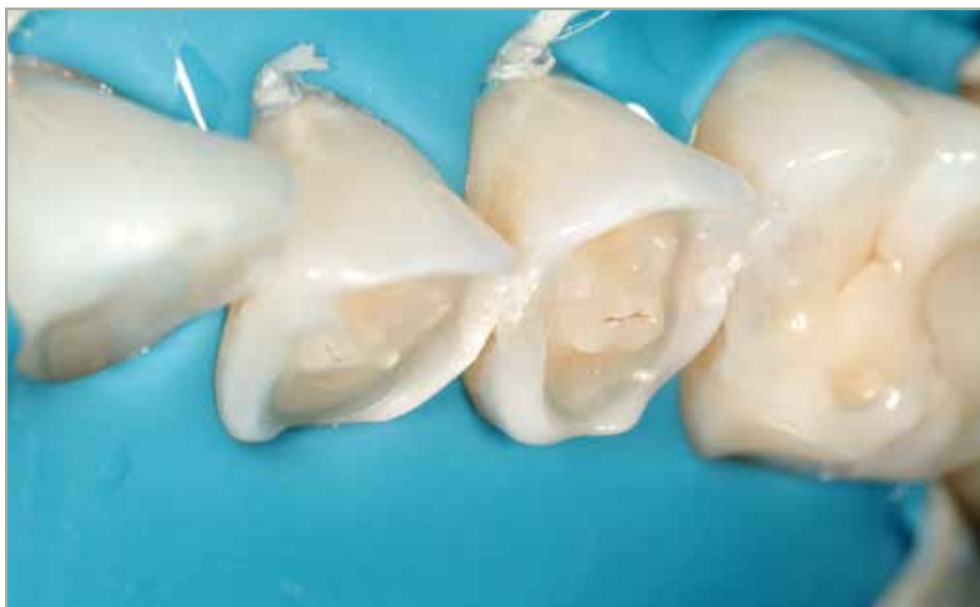Adjunct Professor, Department of Comprehensive Care, Case Western University, Cleveland, Ohio

Private practice and Education Center – The Geneva Smile Center, Switzerland

**Ana Argente**

Assistant, Department of Cariology and Endodontics and Lecturer,

Department of Prosthodontics, School of Dentistry, University of Geneva, Switzerland



Correspondence to: Didier Dietschi

Department of Cariology & Endodontics, School of Dentistry, 19 Rue Barthélémy Menn, 1205 Geneva, Switzerland  
tel: +41 223 829 165/150; fax: +41 223 929 990; e-mail: ddietschi@medecine.unige.ch



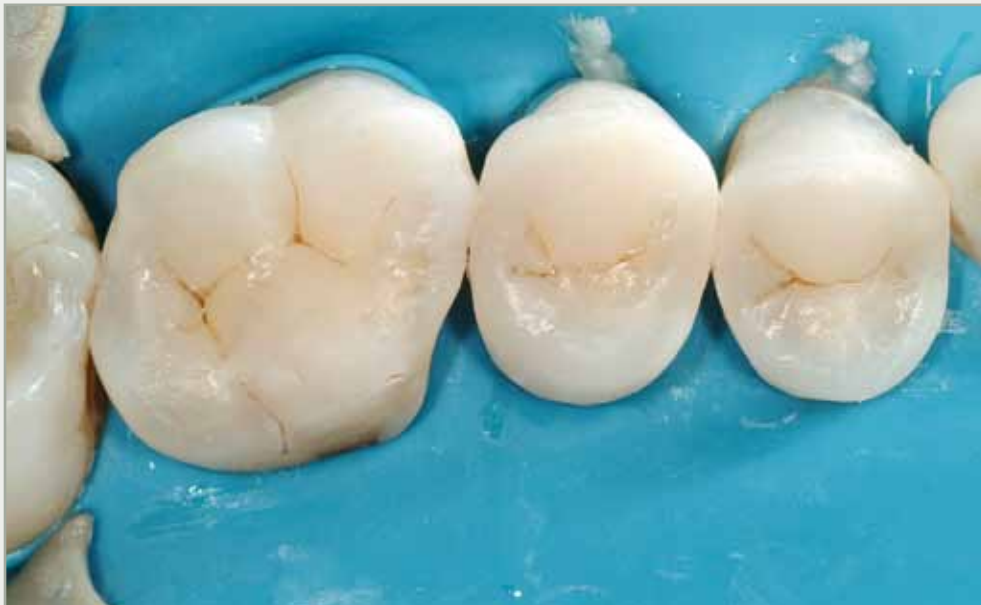## Abstract

This article proposes a comprehensive and conservative approach to the treatment of tooth wear, based on the application of minimally invasive composite restorations to treat both anterior and posterior decay. Three treatment options were considered, in relation to the severity of tissue loss and size of existing posterior restorations. Posterior tooth status actually will guide the clinician toward the most appropriate restorative option. In the presence of limited tissue loss and small fillings, only direct restorations are considered. With moderate tissue loss and medium size existing restorations, a mix of direct and indirect composite restorations is pre-

ferred, and with extensive tissue loss and large restorations, mainly indirect restorations will be chosen. The restoration of anterior guidance and a proper smile line are reestablished using adhesive restorations, including primarily direct composite buildups; in the presence of more severe tissue destruction, loss of facial morphology or discoloration, veneers and possibly crowns can be considered.

The driving force behind the concept presented in this article is to intercept tissue destruction and restore proper tooth biomechanics, function, and esthetics using adhesive restorations which do not further invade hard tissues.

*(Eur J Esthet Dent 2011;6:142–159)*





### Introduction

As outlined in Part I of this article,<sup>1</sup> the incidence of tooth wear and related pathologies are an increasing concern for the dental profession and has multifactorial causes. Behavioral changes, unbalanced diet, and various medical conditions including acid regurgitation or medications influencing saliva composition and flow rate, trigger erosion. In addition, awake and sleep bruxism are widespread functional disorders, which also induce severe tissue attrition. It is important to diagnose early signs of tooth wear so that proper preventive, and if needed, restorative measures can be taken.

In the previous article, a treatment approach was presented which focused on a comprehensive diagnostic and the use of conservative, adhesive restorations to re-create tooth anatomy and esthetics and prevent further tissue destruction. Another important feature of adhesive, direct or indirect tooth-colored partial restorations is to postpone the need for a more invasive prosthetic rehabilitation, which will have a positive biomechanical impact on the long-term maintenance of these patients.<sup>2-5</sup> Actually, the use of adhesive techniques and hybrid composite technology in particular has proven its potential in the treatment of moderate tooth wear.<sup>6-10</sup> Other materials such as lithium di-silicate are used today as an alternative to resin composite due to their improved mechanical properties.<sup>11</sup> Clinical reports have however yet to confirm their satisfactory clinical behavior in such a demanding clinical environment.

Part II of this article will confirm the indications of “minimally” invasive solutions, using mainly partial composite restorations, in the context of tooth wear. This section also aims to describe step-by-step, related clinical procedures.

### Comprehensive treatment outline

The treatment of tooth wear systematically includes three phases, which are: 1) a comprehensive etiological, functional, and esthetic clinical investigation leading to an etiology-based treatment strategy/plan; 2) the preventive and restorative phase; and 3) a maintenance program.

The etiological investigation comprises the identification of general/medical risks or disorders (ie, bulimia nervosa, gastric reflux, hiatal hernia, medications), local risk factors such as bruxism (awake and sleep) and other parafunctional habits, abnormal occlusal conditions, carious activity, periodontal diseases, susceptibility, and saliva alterations (flow, buffer capacity, and compositional changes). After taking any possible action to reduce risk factors, the treatment plan is made, including a functional analysis on mounted casts which leads to a partial (moderate tooth wear) or full waxup (advanced tooth wear). The waxup helps planning and to establish a better occlusal scheme, a suitable vertical dimension of occlusion (VDO) that compensates for tissue loss and creates space for the anterior restorations, and also a more ideal smile line with improved anterior guidance (reducing



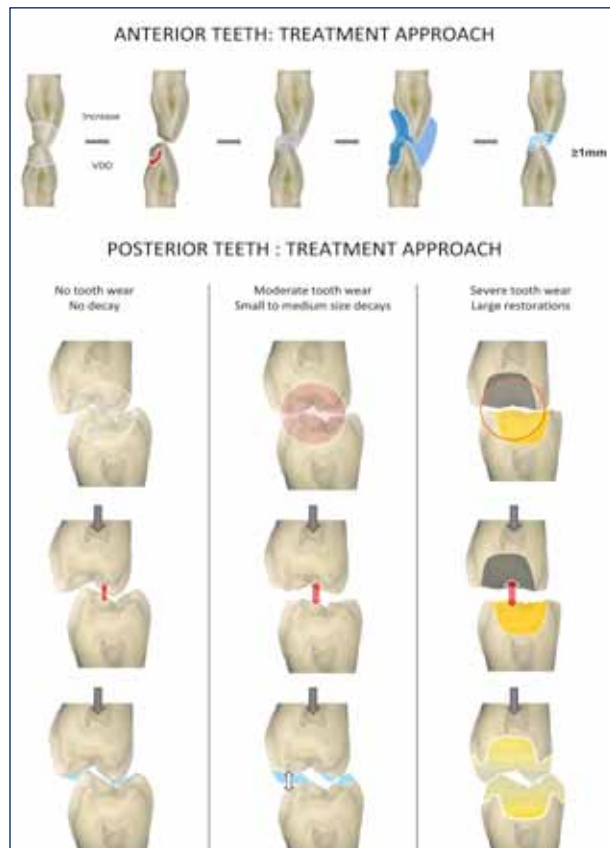
possibly excessive incisal overlap, see Fig 1).<sup>1</sup> Then, the restorative phase can start with the indirect restorations (set at the new VDO) and continue with all direct posterior restorations, enabling the placement of direct and indirect anterior restorations (Fig 1). The maintenance phase systematically includes a protective night guard or other “therapeutic appliance,” regular check-ups, repair or replacement of restorations, when needed.

The idea of increasing the VDO to treat or restore patients with abnormal tooth wear has been described and popularized by Dhal.<sup>12</sup> The rationale was formerly to use a metal appliance to elevate occlusion and allow teeth to move passively until once again in occlusion, and then create space for teeth, which were stabilized by the appliance.<sup>13</sup> The dental movements occur by a supra-eruption of “occlusally free” teeth, together with simultaneous alveolar growth and also intrusion of teeth maintaining contacts. Such phenomena occur in a significant proportion of patients treated according to this concept after a delay of 4 to 8 months.<sup>14-16</sup>

## Treatment strategies for posterior teeth restoration

Even though the perceived treatment need usually takes priority for the patient with anterior teeth, the amounts of tissue loss and restoration size in posterior segments guide the treatment plan. Three conditions are possibly faced with regard to posterior teeth status:

- minimal tissue wear and no restoration



**Fig 1** Anterior teeth: treatment approach – the overall treatment is usually guided by the desired anterior function and smile line. To fulfill these objectives, an increase in the vertical dimension of occlusion is expected; this will be defined on models and fixed by an anterior or full mouth waxup, depending on the extent of anatomical modifications required. An index (resin or silicone) will help the clinician to transfer this information to the mouth. After creating the new posterior occlusion, the final anterior restorations can be placed. Here, a direct composite solution is depicted; in this case, a minimal 1 mm thickness is mandatory to resist functional stresses. Posterior teeth: treatment approach – the choice of restorative material and technique is guided by the amount of tissue wear and size of existing restorations. Left column: with no tooth wear and decay, direct composite restorations are preferred (any composite type). Middle column: in the presence of moderate tooth wear and small to medium size restorations/decays, direct composite restorations are considered (hybrid composites). Right column: In the presence of severe tooth wear and large decays/restorations, indirect tooth-colored restorations will be used (composite preferably or ceramics as well).



- moderate tissue wear and/or small to medium size restorations
- advanced tissue wear and large/metal based restorations.

The treatment rationale and restorative material choice is then based on the aforementioned conditions (Fig 1). With regard to the treatment of anterior teeth, their biomechanical status will drive the clinician toward direct composite or indirect ceramic restorations; treatment rationale and options will be described further below.

### The minimally invasive approach (direct composites only)

In the first two conditions (minimal and moderate tissue wear), the elevation of VDO is usually achieved with the placement of direct composite restorations (Fig 1: left and central columns). When no tissue loss is present, any type of composite can be used (flowable or restorative composite) since occlusal corrections could be only transitory; in this case, the material's wear would be compensated by passive eruption until the reestablishment of direct tooth-to-tooth contacts. The VDO increase will however be maintained through anterior restorations, made with a strong and wear resistant material (composite or ceramics). The most frequent condition however is when moderate tissue wear and small restorations co-exist; then, direct composite restorations are placed using a hybrid composite.<sup>6-7</sup> Even though an indirect technique could be considered to resolve such situation, the benefit of

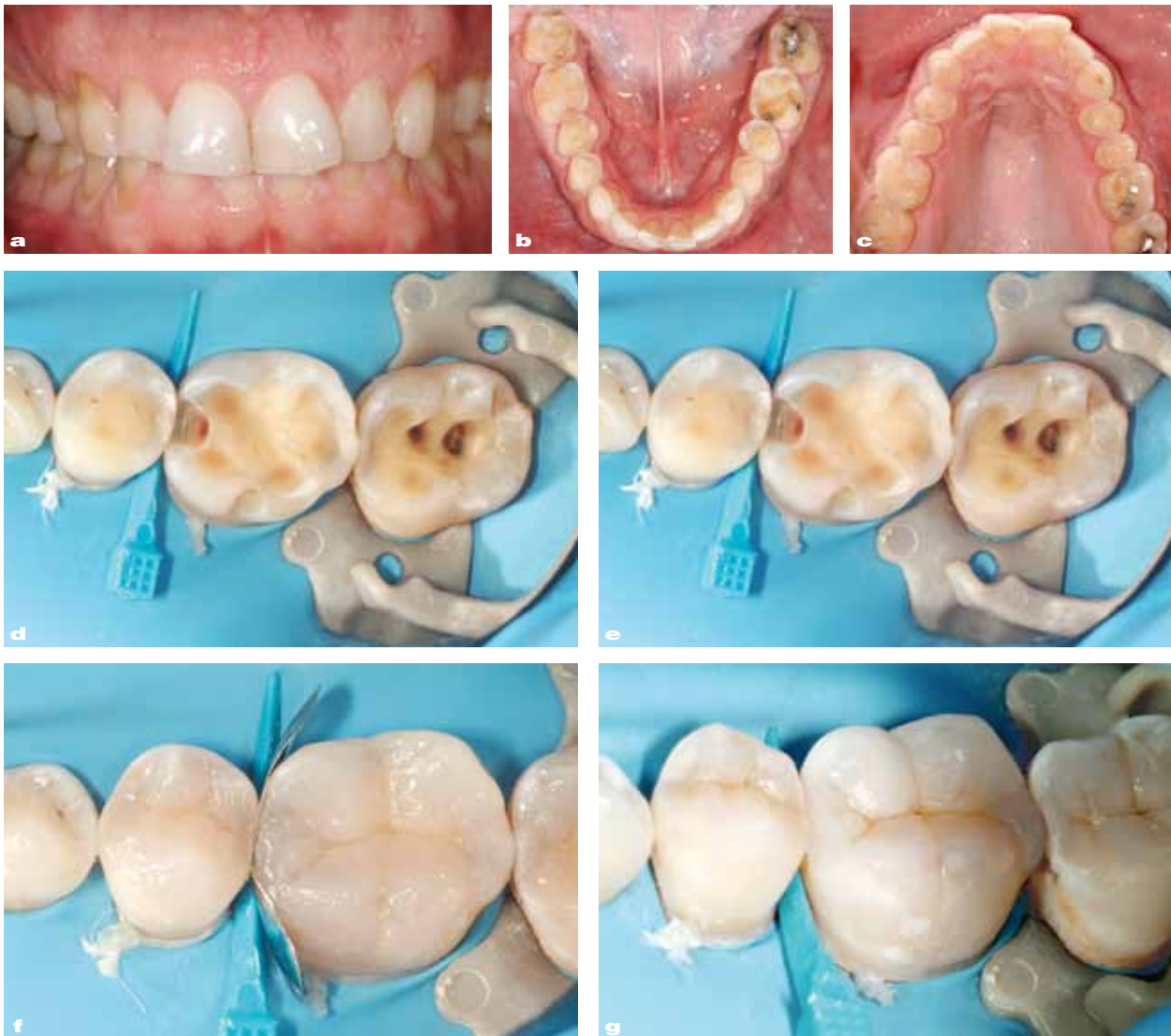using a direct approach is obvious since no marginal preparation or occlusal reduction are needed, and allow restorations to be placed in a limited inter-occlusal space.

The preoperative waxup will guide the anterior and posterior teeth build-ups; therefore, silicone indexes are used to transfer in the mouth, as accurately as possible, the intended occlusal scheme and smile line (Fig 1). Figure 2 illustrates the clinical application of this treatment option.

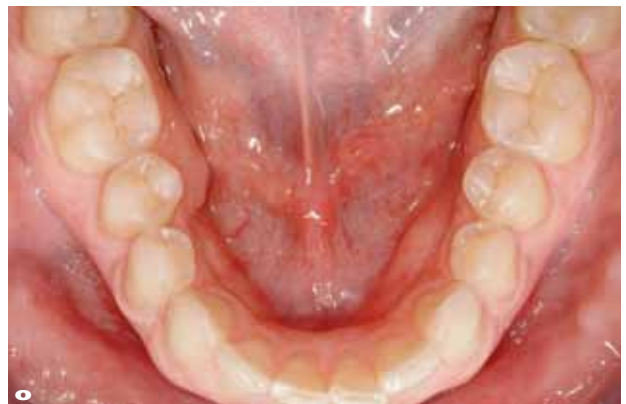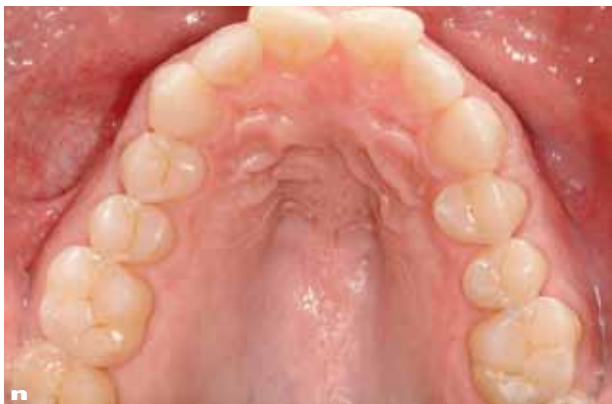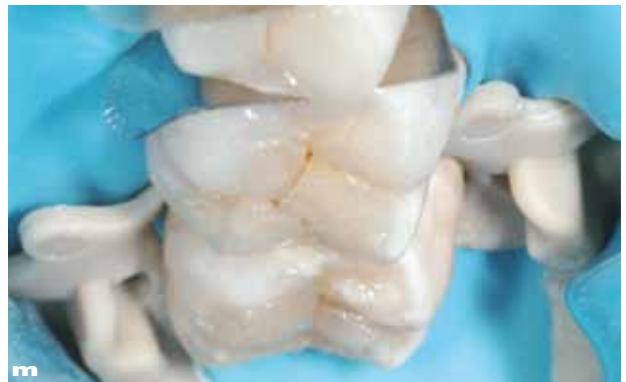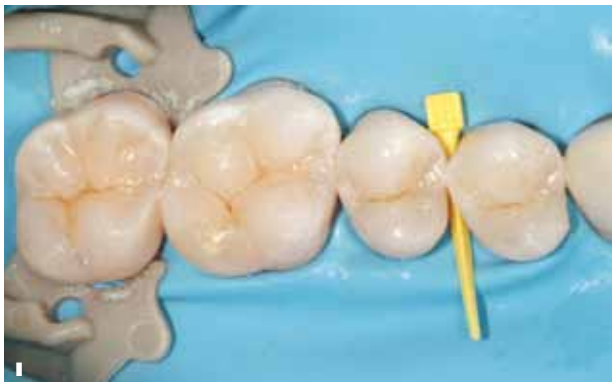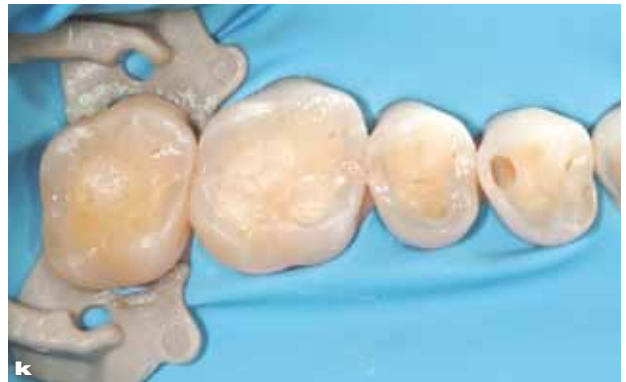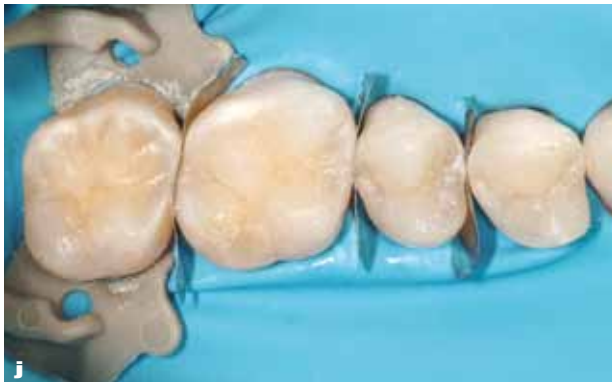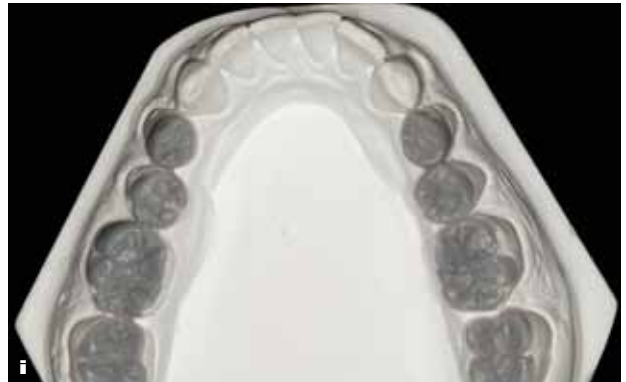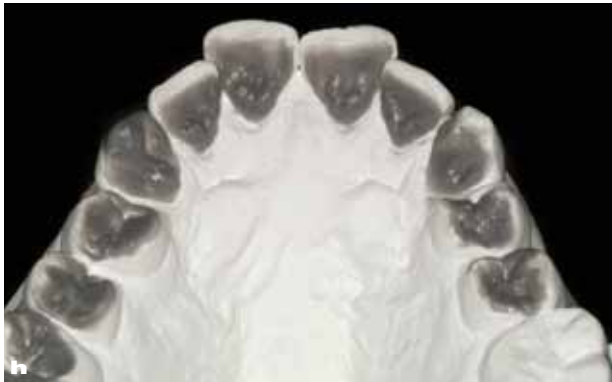
### The conservative approach (direct and indirect partial restorations)

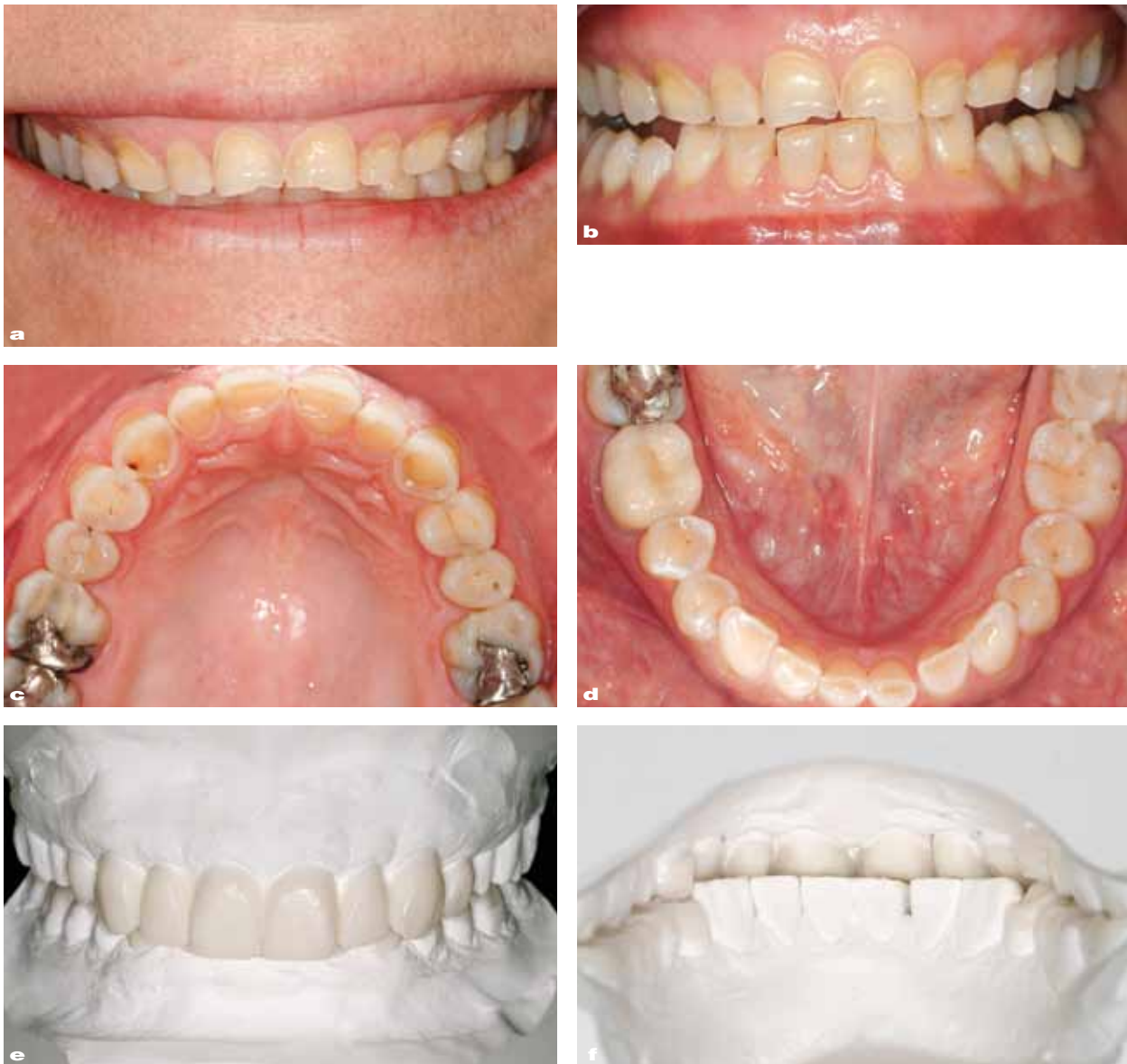
When more tissue wear occurred and/or in the presence of large decays or restorations (especially metal-based ones), a combination of indirect and direct restorations is indicated (Fig 1: right column). Existing tooth-colored restorations showing satisfactory occlusal and proximal adaptation, anatomy, and esthetics can normally be modified after sandblasting and appropriate adhesive surface treatment. Once again, the use of hybrid composites are preferred for the fabrication of onlays and overlays due to a less demanding preparation protocol (it is more feasible to use composite in thinner occlusal space than ceramics) and because of their satisfactory behavior and potential to be repaired.<sup>6-10</sup>

The indirect restorations have to be fabricated first and inserted at the new VDO; then, all direct posterior restorations are placed to complete the posterior rehabilitation. Figure 3 illustrates this second treatment option.



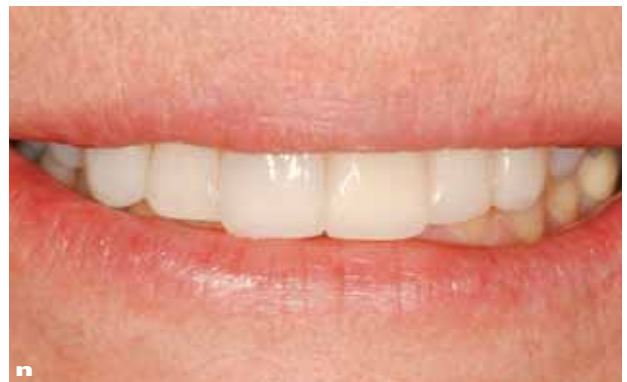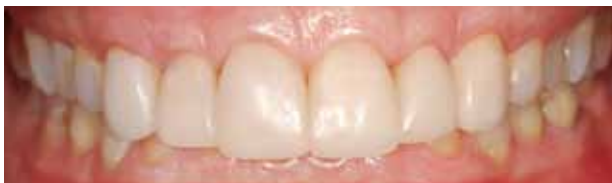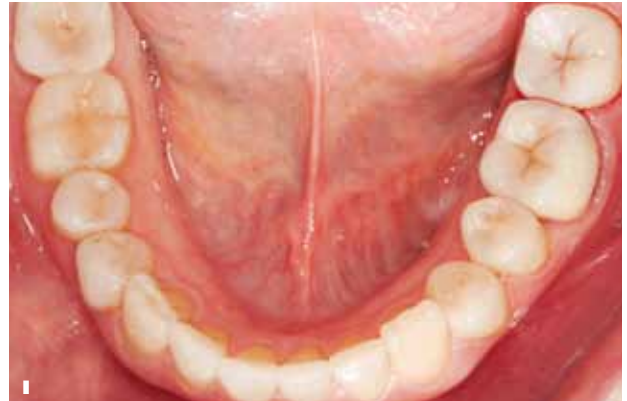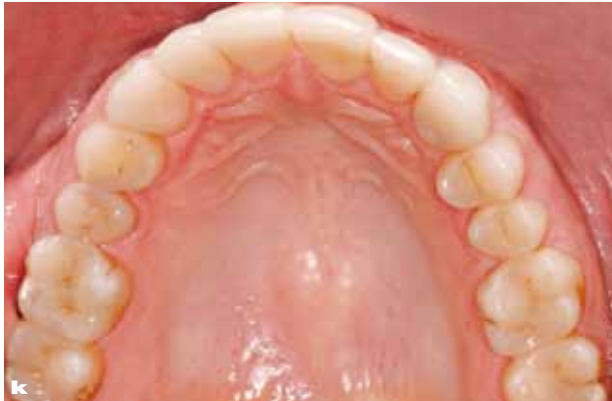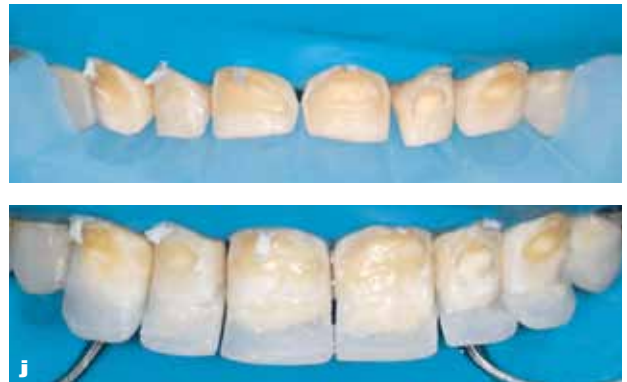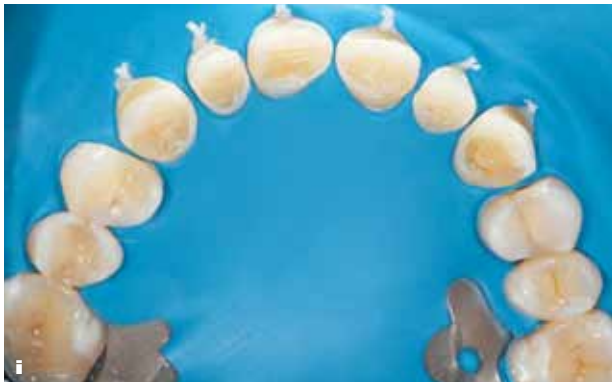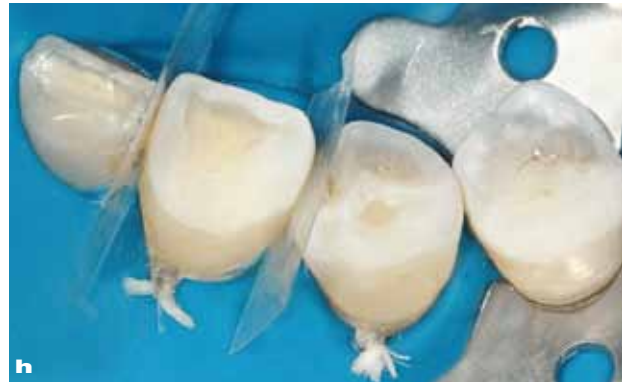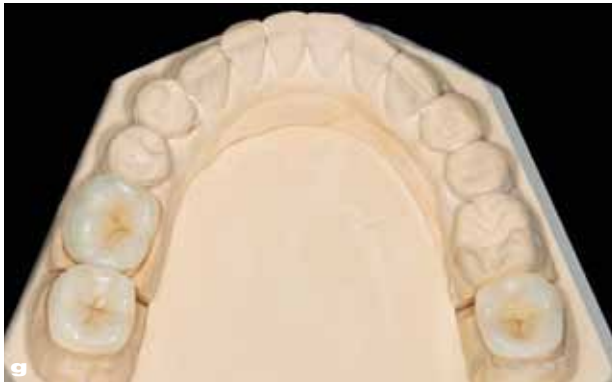**Fig 2 (a–c)** The preoperative situation revealing moderate to severe tooth wear, mainly of erosive origin. However, the amount of tissue loss does not speak in favor of a conventional prosthetic solution; thus, an interceptive solution using direct composite restorations was used in this case. **(d–g)** Treatment of left quadrant. After rubber dam placement, amalgam fillings are removed and tooth surfaces prepared and cleaned with sandblasting, before applying composite. A highly filled hybrid material was used and sculpted before light-curing, enabling proper anatomy and function to be established. **(h–i)** A full mouth waxup is often made prior to treatment to serve as a reference and establish the new vertical dimension of occlusion (VDO) also when a direct restorative approach is followed. Silicone indexes can serve to buildup lingual and buccal cusps at the right level, when needed. **(j–m)** The same treatment sequence is applied to the maxillary quadrants. These views show that composite serves both to fill existing cavities and replace eroded or worn tissues. **(n–o)** Completed functional restoration of both maxillary and mandibular posterior surfaces, using only direct restorations; such an approach is highly conservative, comfortable for the patient due to the short treatment time, and cost-effective.

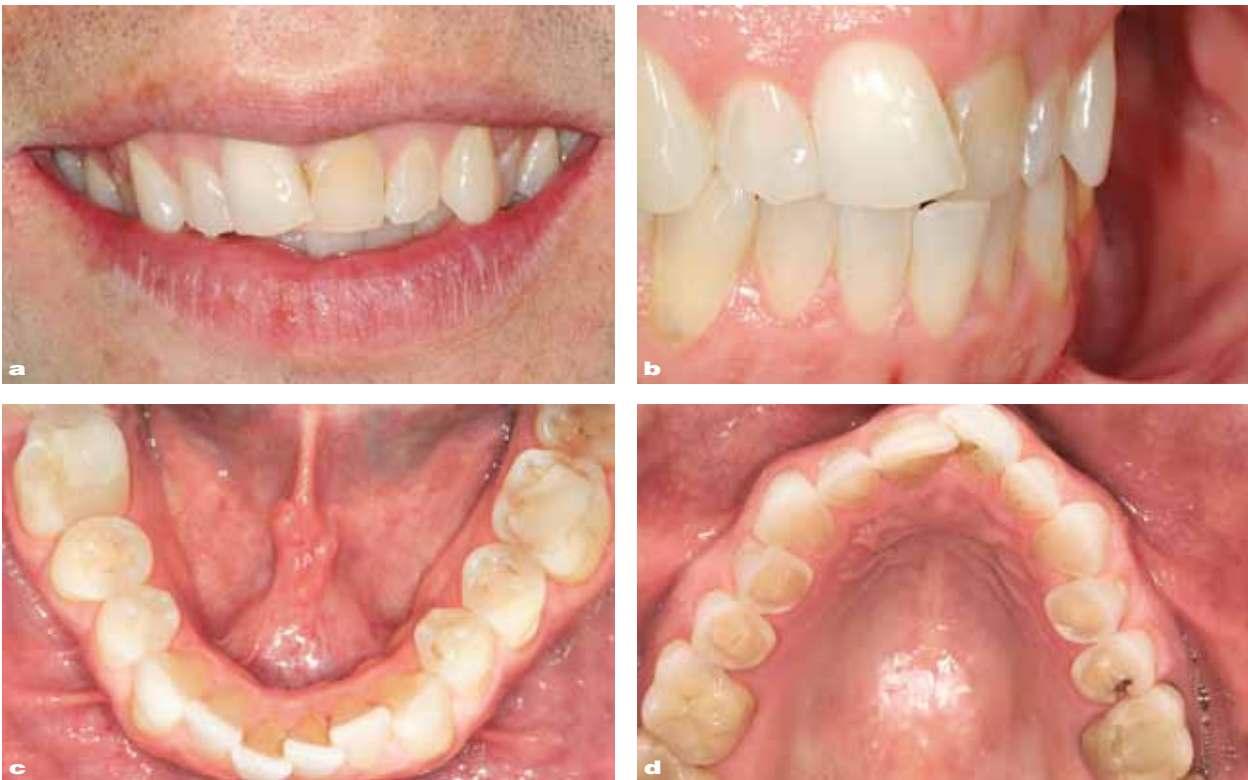



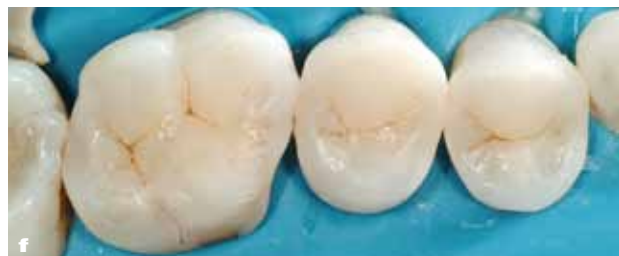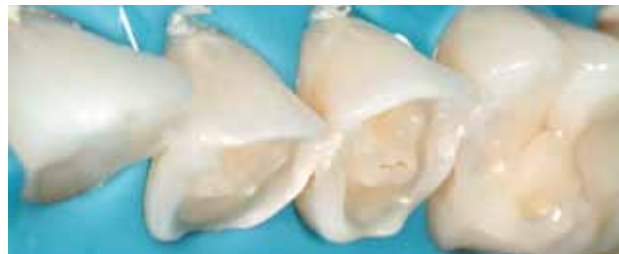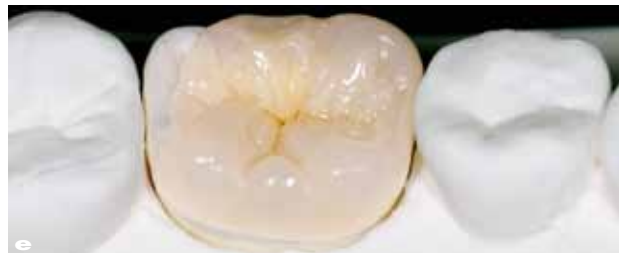**Fig 3 (a-d)** Preoperative situation revealing severe erosion of the lingual surfaces of maxillary anterior teeth as well as generalized tooth wear due to a combination of tooth attrition and erosion. The extent of existing restorations on mandibular molars associated with the need to increase the vertical dimension of occlusion (VDO) favors here a combined solution, using indirect ceramic and direct composite restorations. **(e-f)** A full mouth waxup is also needed to establish the new VDO prior to treatment onset and serves to plan all restorative steps according to a proper functional scheme and improved smile line. **(g)** When indirect restorations such as onlays, overlays or crowns are needed, they must be fabricated at the new VDO and inserted first; then, all direct restorations can be made accordingly. **(h-j)** All direct restorations needed for both maxilla and mandible are made in two or three sessions to allow proper occlusal balance and function to be re-established as quickly as possible. The rehabilitation of the smile line and new anterior guidance were made here with a direct approach, using a silicone index made from the waxup; this enables this crucial procedure to be performed with precision and predictability. **(k-n)** These are occlusal and frontal views of the mixed rehabilitation, using a combination of indirect ceramic restorations and direct composites to reverse tooth wear impact on function, biology, and esthetics.

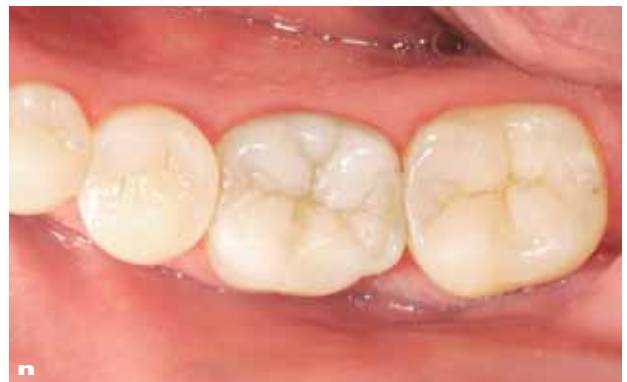
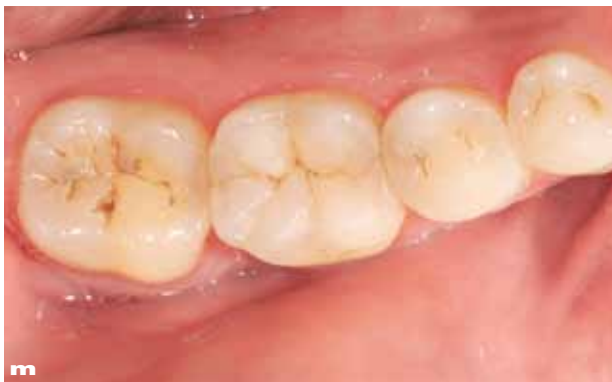
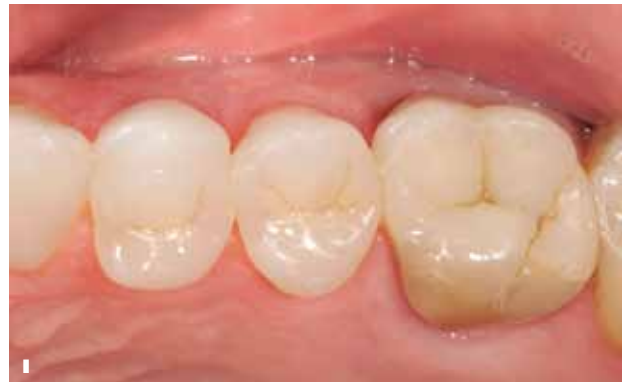
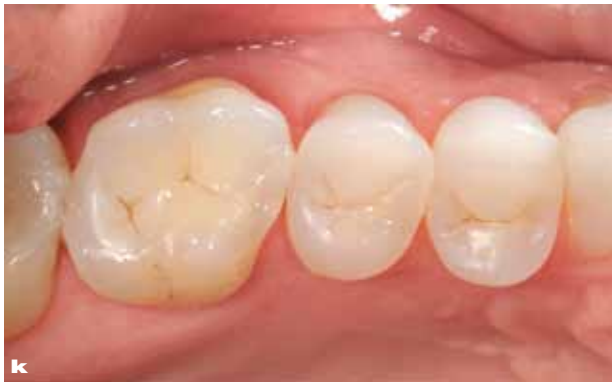
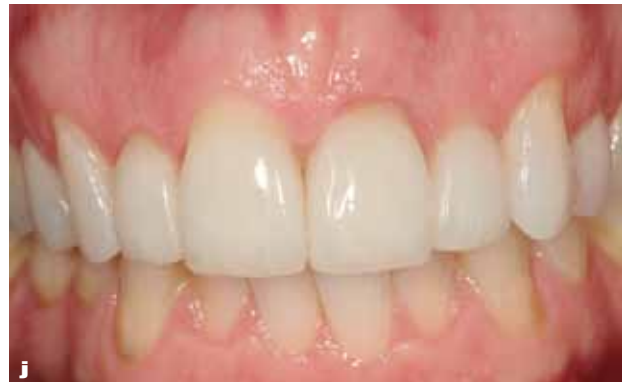
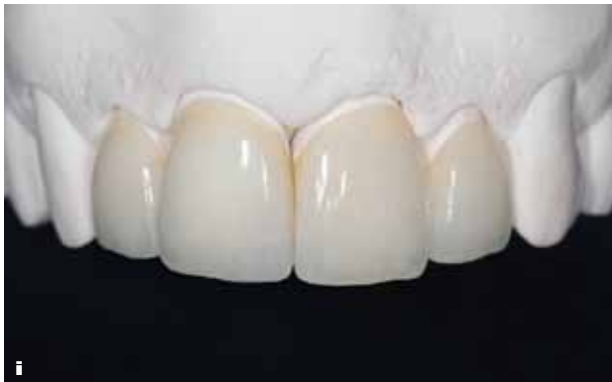
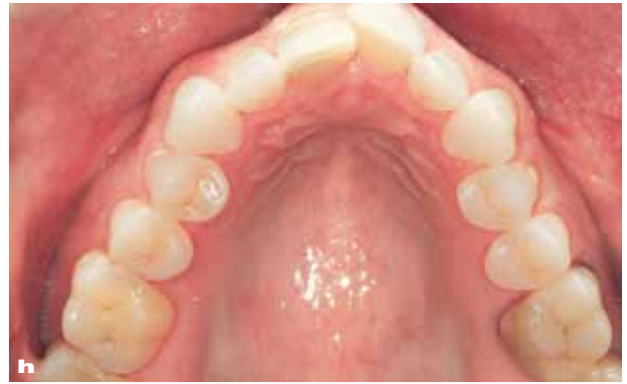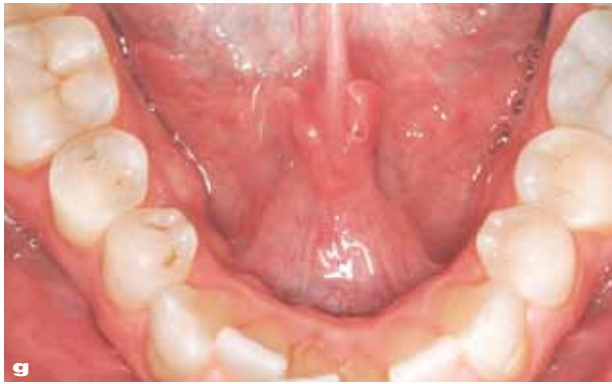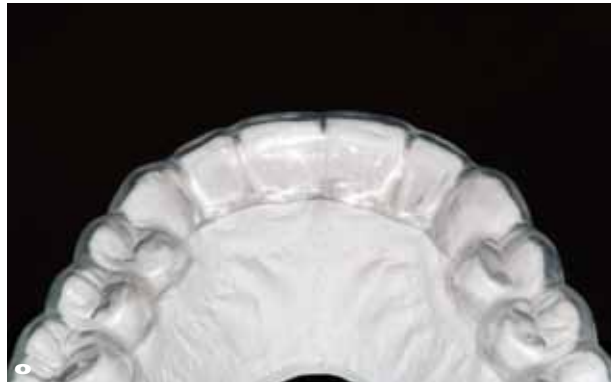
**Fig 4 (a-d)** Preoperative situation showing a severe erosion of the lingual surfaces of maxillary anterior teeth as well as generalized erosion of occlusal surfaces. Several restorations were to be replaced due to improper marginal adaptation and some other teeth showed active decay. The patient was willing to correct the significant crowding of the maxillary front teeth; most of those teeth were in a reclined position, making an orthodontic solution rather difficult and time consuming, which the patient refused. A mixed approach was selected: indirect and direct composite restorations were chosen to restore posterior teeth while micro-invasive porcelain veneers were used to correct the maxillary anterior teeth positions. **(e-f)** Indirect and direct composite restorations allowed for the treatment of decay and the restoration of proper tooth anatomy and function at a new VDO, creating the space required to also restore the lingual surfaces of maxillary front teeth. **(g and h)** Both maxillary and mandibular posterior occlusal views showing improved tooth anatomy and function. **(i and j)** Porcelain veneers were made to correct the buccal profile of teeth #12 to #22. Preparations were minimally invasive on three of these teeth, tooth #11 being the only one to be prepared micro-invasively to correct rotation. Canines were left untouched and the maxillary premolar buccal profile was modified by direct composite veneers.







**Fig 4 (continued) (k-n)** Two-year postoperative views demonstrating the satisfactory stability and performance of composite restorations to correct the consequence of tooth wear and to prevent further biomechanical impact of conventional prosthodontics. **(o)** A vacuum formed, relatively thin night guard is prepared for all patients at the end of the phase to protect both the restorations and residual tooth structure from attrition. The compliance of patients with such thin night guards proved largely superior to conventional thicker “therapeutic” splints.



## Hybrid and indirect ceramic rehabilitation

In the case of severe tissue loss and erosion, or if abfraction lesions have significantly affected buccal and lingual surfaces, the benefit of a partial restoration is less obvious; therefore, full tooth coverage might be the more realistic and effective solution (Fig 4).

## Treatment of anterior teeth – rationale and various options

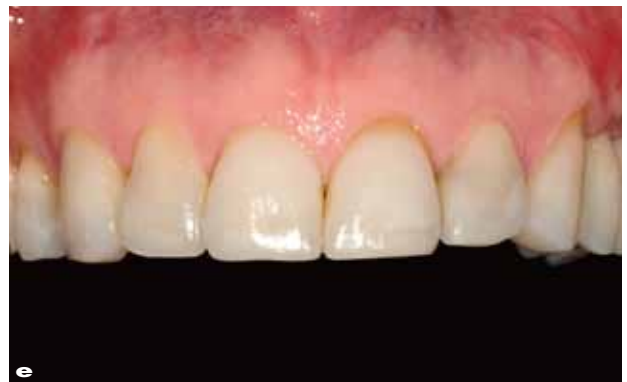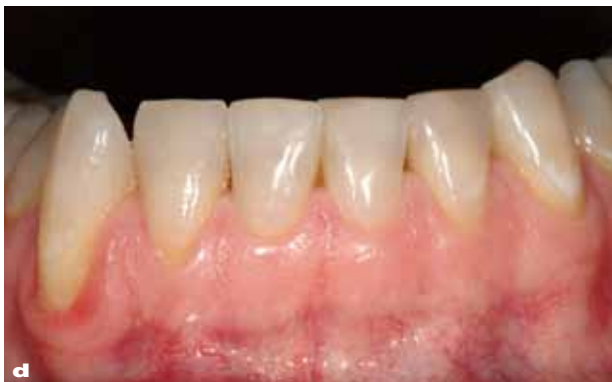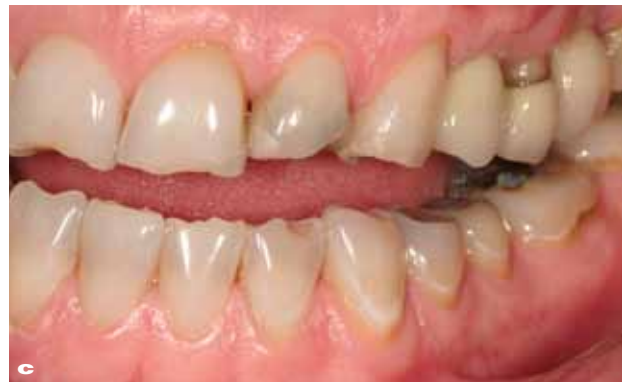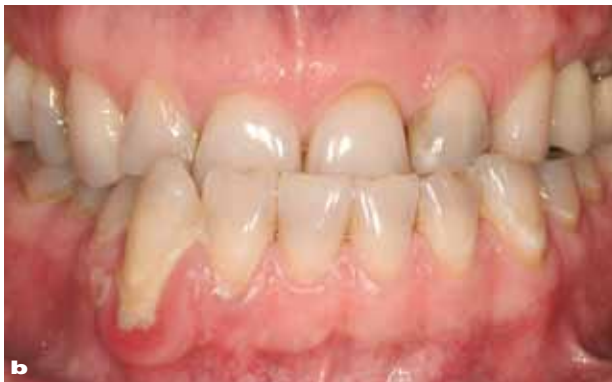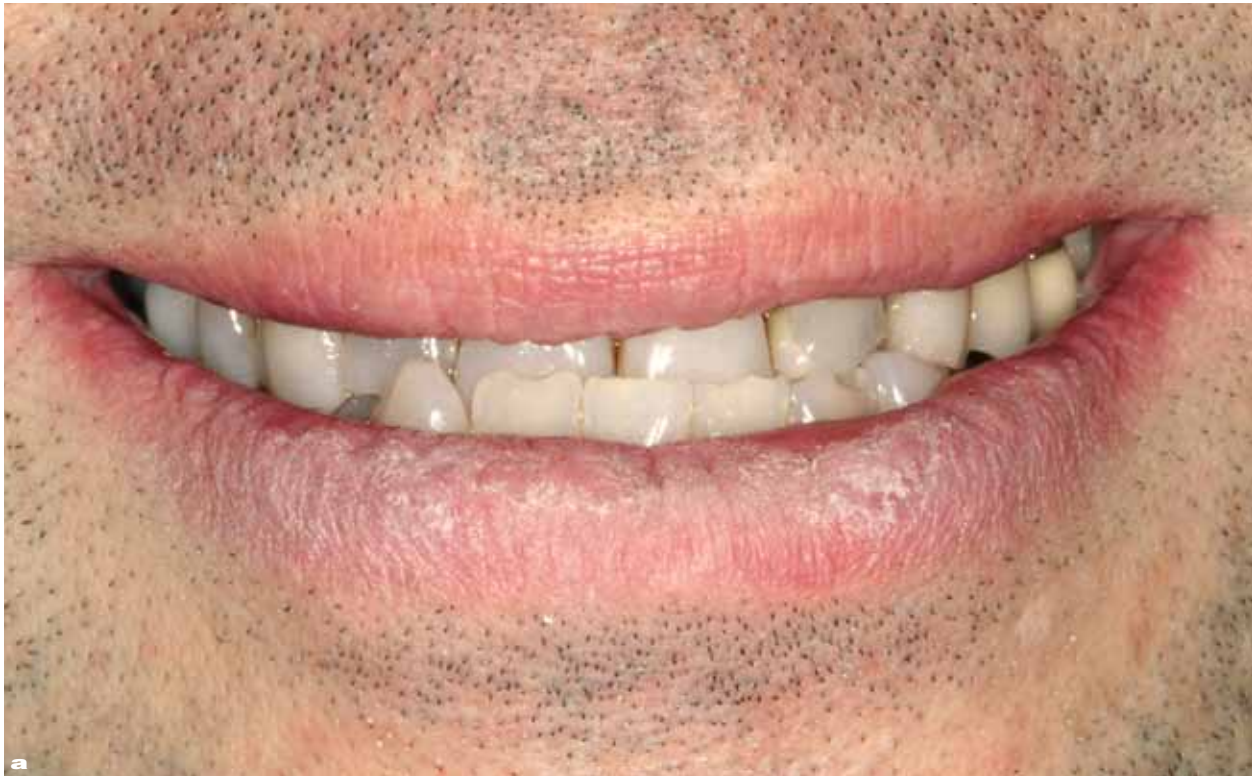Whenever possible, the direct option is preferred in all cases of moderate anterior tooth wear (Figs 1 and 2). The condition for applying a direct restoration, or conversely, to avoid a veneering technique or full tooth preparation is the persistence of an intact buccal anatomy and rather satisfactory alignment of front teeth.

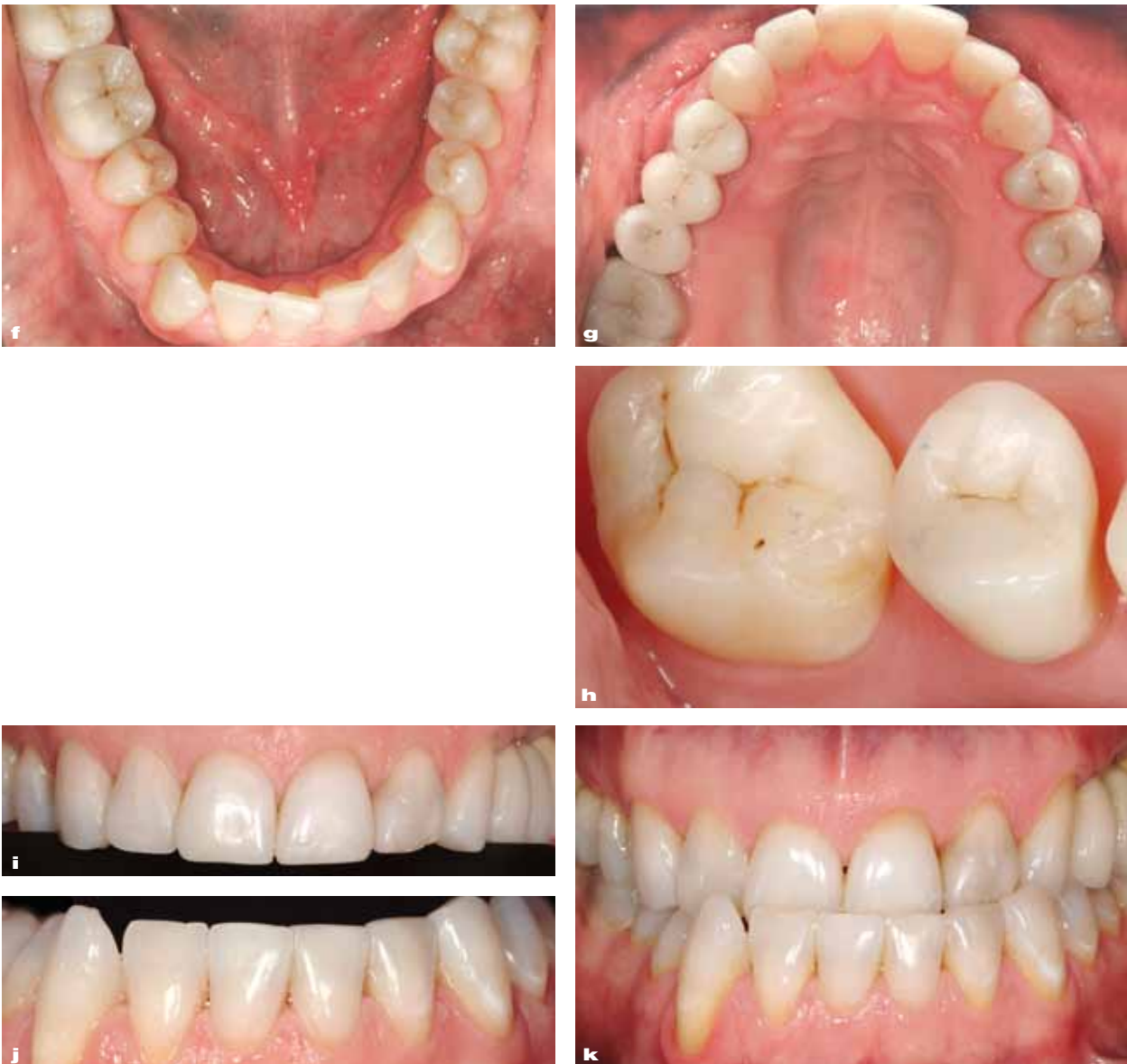A “biomechanical” rule, which is based mainly on the author’s experience, is that a strict minimum of 1.0 mm of material is needed on the restored incisal edge to avoid mechanical failures and the need for frequent repairs. Even if this guideline is respected, it is

not a guarantee that no chipping or detachment will occur. Of course, the night guard will play an important role; it is fabricated for the arch, which received the more “delicate” restorations. In cases of erosion, this risk factor might not be as predominant as in patients showing episodes of severe bruxism.

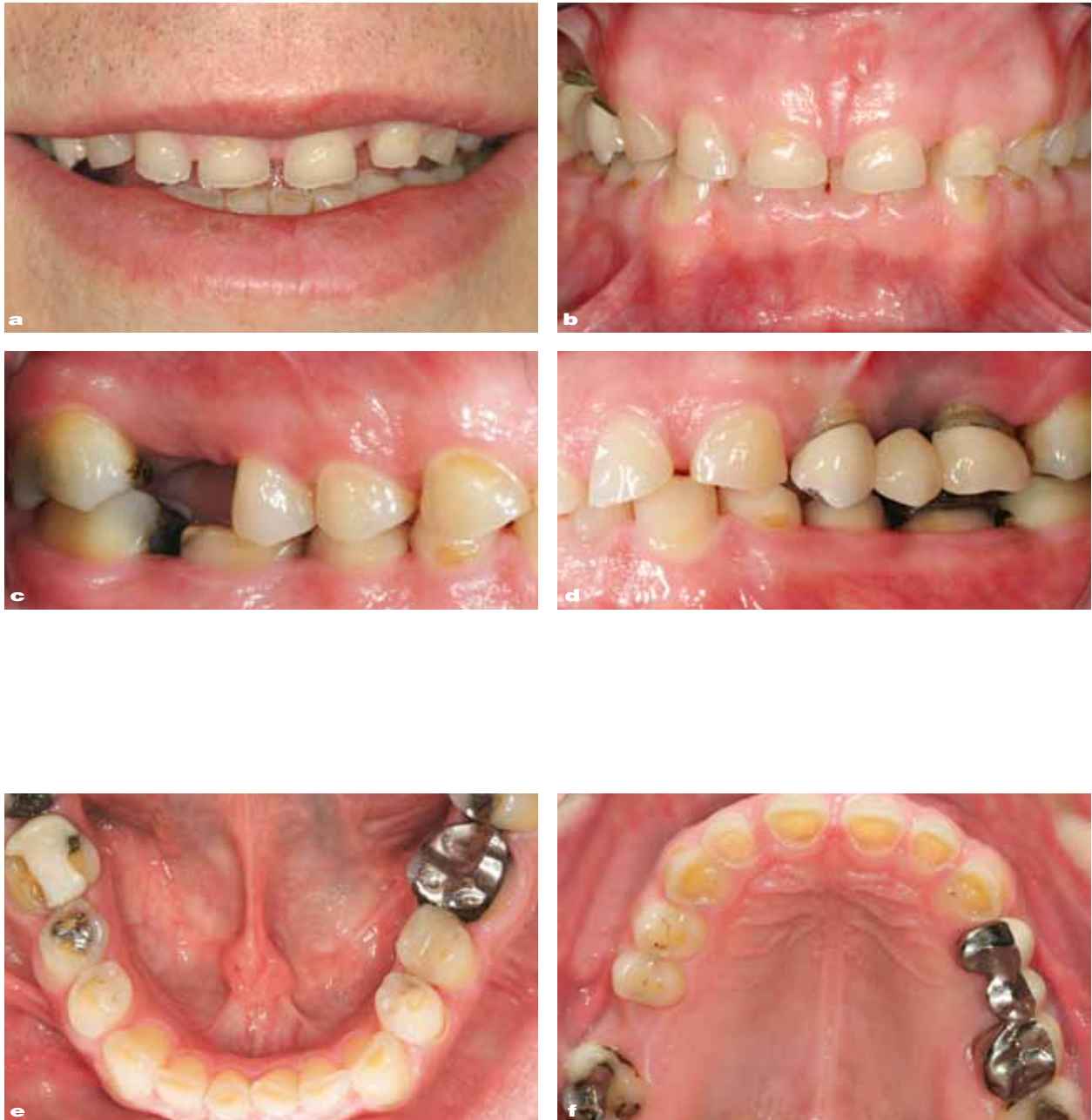In the presence of eroded buccal surfaces, more severe tissue destruction and slight to moderate misalignment, a veneering approach is required. On the lingual side however, a direct composite application is often chosen because of its simplicity and efficacy. An alternative is the placement of indirect lingual composite veneers, such those described by Vailatti and co-workers.<sup>17-19</sup> Figures 4 and 5 illustrate various combinations of adhesive, conservative restorative solutions for anterior tooth wear.

It is only in the case of total, or near total, enamel loss and anatomy (or severely decayed teeth) that full crowns would be appropriate. However the amount of additional tooth preparation and the potential impact on tooth vitality and biomechanics are to be considered before choosing this option (Fig 6).

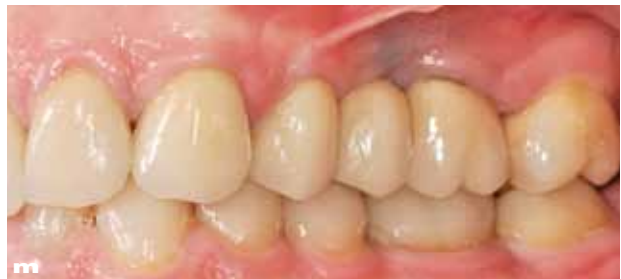
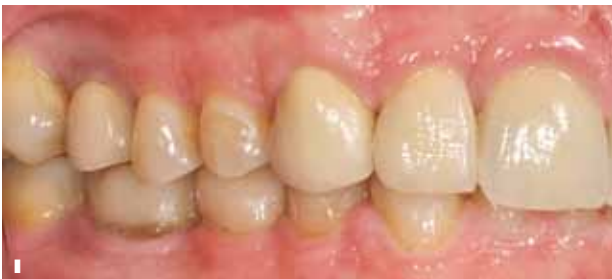
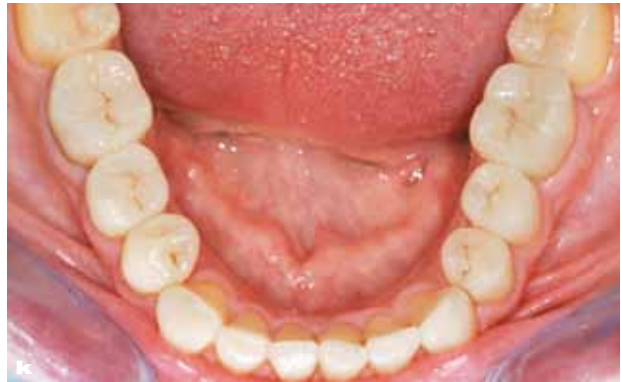
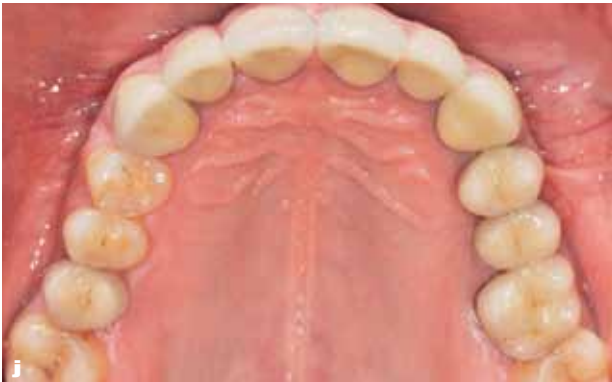
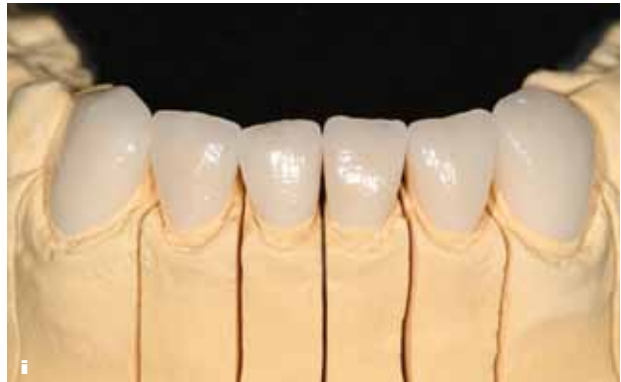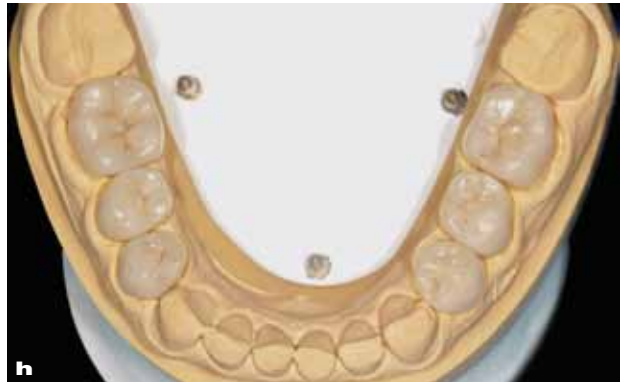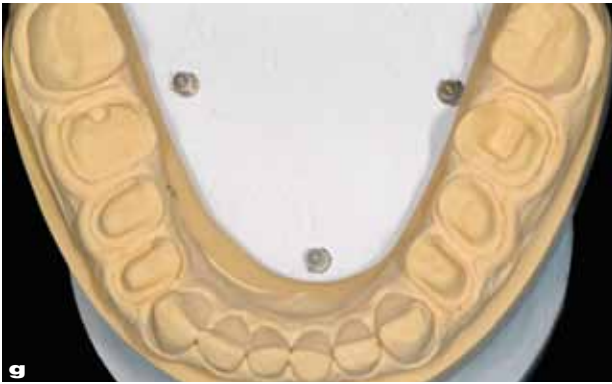**Fig 5 (a-c)** Preoperative situation revealing a Class III occlusion associated with severe tooth attrition. Numerous large posterior restorations are present as well as two implants to replace teeth #24 and #26. There is also positional attrition of the lingual surfaces of maxillary anterior teeth, as well as generalized tooth wear due to a combination of tooth attrition and erosion. The extent of existing restorations on mandibular molars associated with the need to increase the vertical dimension of occlusion (VDO) favors here a combined solution, using indirect composite and ceramic restorations and/or direct composite. **(d-e)** Maxillary and mandibular front teeth were restored with direct composite restorations, after proper VDO correction. **(f-g)** Occlusal views showing mixed rehabilitation using indirect (teeth #46 to #48 and #36) and direct composite restorations as well as an implant-supported bridge (#24 to #26). **(h-k)** Two-year views demonstrating the good performance of composite restorations despite the parafunctional environment; the patient actually confirmed that he did not wear the night guard over this period. Some minor mechanical degradation occurred on a few teeth (#22 and #16); such “failures” can be easily repaired with fresh composite after proper surface treatment (sandblasting, silane, and bonding).



**Fig 6 (a-f)** Preoperative situation showing generalized tooth wear due to a combination of tooth attrition and erosion. In the absence of a few teeth and existing prosthetic restorations, a new prosthetic rehabilitation was planned with an increased VDO. This case demonstrates the difference between an interceptive adhesive approach and a classic prosthetic approach. **(g-h)** Indirect posterior mandibular restorations and related working model showing that the space needed to fabricate indirect ceramic restorations that exhibit proper mechanical strength is impacting residual tooth structure and tooth biomechanics. **(i)** The mandibular incisors were restored with porcelain veneers. **(j-m)** Buccal and occlusal views of the finished rehabilitation. The postoperative status shows improved functional balance, smile configuration, and VDO through a full mouth prosthetic rehabilitation. Such a satisfactory result, however, was achieved at higher biomechanical and financial costs.







### Complications and repair

The more likely complications of a composite restoration are wear and chipping (partial failure) while full loss or detachment (total failure) is an unlikely occurrence.<sup>6-10</sup> Figures 4k to 4n and Figures 5f to 5k illustrate the satisfactory performance of hybrid composites, even in a critical biomechanical environment. Composite chipping or limited fractures can be easily repaired. Then, surfaces are sandblasted and fresh composite re-applied after proper adhesive procedures (etching enamel and bonding all surfaces). In fact, the worst-case scenario would be the full replacement of the restoration, normally a rather uncomplicated procedure, implying moderate cost in comparison with a conventional prosthetic restoration.

### Conclusions

Parts I and II of this article have proposed a comprehensive and conservative approach to the treatment of moderate tooth wear, based mainly on the application of minimally invasive composite restorations to treat both anterior and posterior decays. The combination of appropriate preventive and maintenance measures has the best potential as a treatment concept to restore and stabilize tooth biomechanics, and avoid or postpone a more costly and invasive prosthetic solution.

Three treatment options were considered, in relation to the severity of tissue loss and the extent of existing restorations in the posterior segments. In fact, posterior tooth status determines

what the more appropriate restorative option is.

In the presence of 1) limited tissue loss and small fillings, direct restorations only are usually considered; 2) moderate tissue loss and medium-size existing restorations, a mix of direct and indirect composite restorations is then preferred; and 3) extensive tissue loss and large restorations, indirect restorations mainly will be selected. As regard the restoration of anterior guidance and the restoration of proper smile line and tooth proportions, adhesive restorations are also preferred, including primarily direct composite buildups. In the presence of more severe tissue destruction, loss of facial morphology or discoloration, then veneers and possibly crowns can be used.

Finally, the driving force behind the concept presented in these two articles is to intercept tissue destruction and restore proper tooth biomechanics, function, and esthetics using adhesive restorations which do not further invade hard tissues.

### Acknowledgments

We would like to thank Mr Serge Erpen (oral pro, Geneva, Switzerland) for the waxup and fabrication of indirect restorations presented in Figures 2h to i, 4e and Figure 5. We would like to thank Mr Patrick Schnyder (oral design, Montreux, Switzerland) for the fabrications of veneers presented in Figures 4j to k. We would also like to express our gratitude to the Dental School dental laboratory of the University of Geneva (Switzerland) for the fabrication of the indirect restorations presented in Figures 3 and 6, as well as to Dr Claude Crottaz, senior lecturer at the Department of Fixed Prosthodontics (University of Geneva), for his support and supervision of the case presented in Figure 6.



## References

1. Dietschi D, Argente A. A comprehensive and conservative approach for the restoration of abrasion and erosion. Part I: concepts and clinical rationale for early intervention using adhesive techniques. *Eur J Esthet Dent* 2011;6:20–33.
2. Ibsen RL, Ouellet DF. Restoring the worn dentition. *J Esthet Dent* 1992;4:96–101.
3. Christensen G. A new technique for restoration of worn anterior teeth. *J Am Dent Assoc* 1995;126:1543–1547.
4. Darbar UR, Hemmings KW. Treatment of localized anterior toothwear with composite restorations at an increased occlusal vertical dimension. *Dent Update* 1997;24:72–5.
5. Marais JT. Restoring palatal tooth loss with composite resin, aided by increased vertical height. *SADJ* 1998;53:111–9.
6. Hemmings KW, Darbar UR, Vaughan S. Tooth wear treated with direct composite restorations at an increased vertical dimension: results at 30 months. *J Prosthet Dent* 2000;83:287–293.
7. Bartlett D, Sundaram G. An up to 3-year randomized clinical study comparing indirect and direct resin composites used to restore worn posterior teeth. *Int J Prosthodont* 2006;19:613–617.
8. Redman CD, Hemmings KW, Good JA. The survival and clinical performance of resin-based composite restorations used to treat localised anterior tooth wear. *Brit Dent J* 2003;194:566–572.
9. Poyser NJ, Briggs PF, Chana HS, Kelleher MG, Porter RW, Patel MM. The evaluation of direct composite restorations for the worn mandibular anterior dentition – clinical performance and patient satisfaction. *J Oral Rehabil* 2007;34:361–376.
10. Smales RJ, Berekally TL. Long-term survival of direct and indirect restorations placed for the treatment of advanced tooth wear. *Eur J Prosthodont Restor Dent* 2007;15:2–6.
11. Clausen JO, Abou Tara M, Kern M. Dynamic fatigue and fracture resistance of non-retentive all-ceramic full-coverage molar restorations. Influence of ceramic material and preparation design. *Dent Mater* 2010;26:533–538.
12. Dahl BL, Krogstad O. The effect of a partial bite raising splint on the occlusal face height. An x-ray cephalometric study in human adults. *Acta Odontol Scand* 1982;40:17–24.
13. Briggs PF, Bishop K, Djemal S. The clinical evolution of the 'Dahl Principle'. *Br Dent J* 1997;183:171–176.
14. Gough MB, Setchell DJ. A retrospective study of 50 treatments using an appliance to produce localised occlusal space by relative axial tooth movement. *Br Dent J* 1999;187:134–139.
15. Saha S, Summerwill AJ. Reviewing the concept of Dahl. *Dent Update*. 2004;31:442–444, 446–447.
16. Poyser NJ, Porter RW, Briggs PF, Chana HS, Kelleher MG. The Dahl Concept: past, present and future. *Br Dent J* 2005;198:669–676.
17. Vailati F, Belser UC. Full-mouth adhesive rehabilitation of a severely eroded dentition: the three-step technique. Part 1. *Eur J Esthet Dent* 2008;3:30–44.
18. Vailati F, Belser UC. Full-mouth adhesive rehabilitation of a severely eroded dentition: the three-step technique. Part 2. *Eur J Esthet Dent* 2008;3:128–146.
19. Vailati F, Belser UC. Full-mouth adhesive rehabilitation of a severely eroded dentition: the three-step technique. Part 3. *Eur J Esthet Dent* 2008;3:236–257.